

Programmed Death Ligand 1 (PD-L1) Immunohistochemistry

Clinician

Clinician Name: Dr Chandra Gouda
Medical Facility: BLK Cancer Center
Pathologist: Not Provided

Test Description

This test is useful for identification of neoplasms expressing programmed cell death 1-ligand 1 (clone SP263). PD-L1 also known as B7 homolog 1 (B7-H1) or CD274, is a transmembrane protein involved in the regulation of cell-mediated immune responses through interaction with the receptor programmed death protein-1 (PD-1). PD-L1 has been identified as both a prognostic and theranostic marker in a variety of neoplasms. Overexpression of PD-L1 has been observed in carcinomas of the urinary bladder, lung, thymus, colon, pancreas, ovary, breast, kidney, and in melanoma and glioblastoma.

Specimen

Sample Type: FFPE block S-1650/19 B
Site: Sigmoid Colon
Pathology ID: MOLQ/IHC-31072019
Disease: Metastatic Moderately Differentiated Adenocarcinoma of Colon

Interpretation

The scoring system is based on type and origin of tumor. If additional interpretation or analysis is needed, send request for Pathology Consultation.

Methodology

Immunostaining for PD-L1 protein was done using Ventana Rabbit Anti-Human PD-L1/CD274 Monoclonal Antibody (Clone SP-263) on Ventana Autostainer.

Positive PD-L1 staining/expression is defined as complete and/or partial, circumferential or linear plasma membrane or cytoplasmic staining at any intensity that can be differentiated from background.

Note

Preclinical studies suggest that positive programmed cell death 1-ligand 1 (PD-L1) immunohistochemistry in tumor cells may predict tumor response to therapy with immune checkpoint inhibitors. This result should not be used as the sole factor in determining treatment, as other factors (eg, tumor mutation burden and microsatellite instability) have also been studied as predictive markers.

References

1. Rosai and Ackerman's Surgical Pathology.
2. Modern Surgical Pathology.
3. PD-L1 and gastric cancer prognosis: A systematic review and meta-analysis. Lihu Gu, Manman Chen, Dongyu Guo, Hepan Zhu, Wenchao Zhang. PLOS ONE August 2017
4. Immunotherapy in Advanced Gastric Cancer: An Overview of the Emerging Strategies Helena Magalhães, Mário Fontes-Sousa, and Manuela Machado. Canadian Journal of Gastroenterology and Hepatology, Volume 2018, 8 pages
5. Immunotherapy in Prostate Cancer: Recent Advances and Future Directions Ida Silvestri et al. EMJ Urol. 2019;7[1]:51-61.

Programmed Death Ligand 1 (PD-L1): Positive

Microscopy Evaluation

HE Staining (Figure 1)

Tumor cells: 30%

Immune cells: 40%

Tumor cells positive for PD-L1 (membranous + cytoplasmic only): 60%
(Moderate)

Immune cells positive for PD-L1: 02%
(Moderate)

HE Stained Section

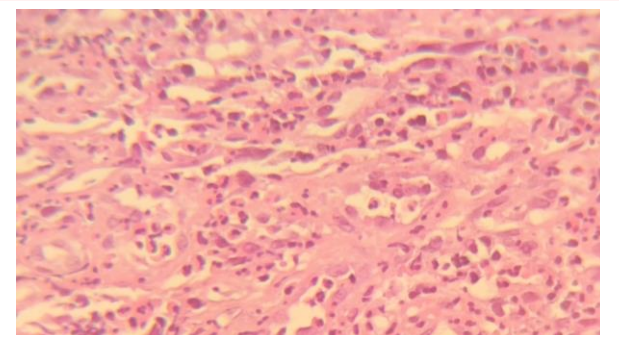


Figure 1

PD-L1 IHC- Tumor Cells

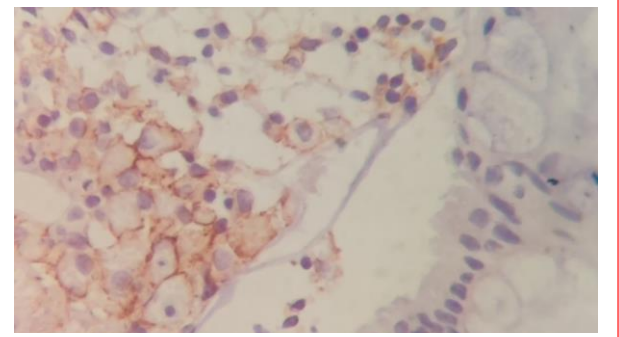


Figure 2

PD-L1 IHC- Immune Cells

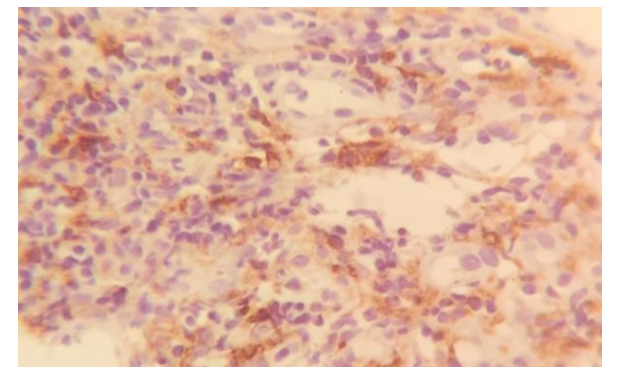


Figure 3

Reviewed By



Dr. Gulshan Yadav, MD

Head, Pathology

MOLQ Laboratory (A Unit of Molecular Quest Healthcare Pvt. Ltd.)

Reference Laboratory: 28-29, Sector-18 (P) | Gurgaon, Haryana, 122015 | Phone 0124 - 4307906, Fax 0124 - 4278596 | Email: contact@molq.in