

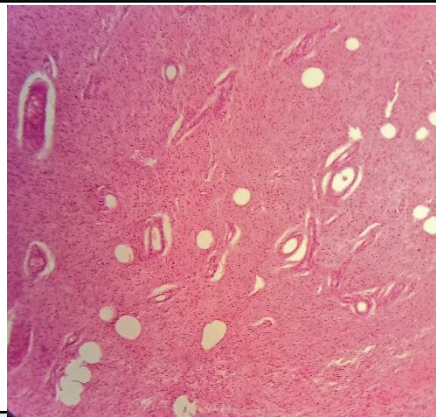
<b>Patient Name</b> Mr. AB SATAR 3413TREHGAM CHOWK	<b>Client</b> Apollo Laboratories CC, Jammu & Kashmir	<b>Specimen Received</b> 16/07/2019
<b>Age/Sex</b> 70 Years/Male	<b>Ref. Doctor</b> DR AB KHALIQ MS	<b>Specimen Type</b> Tissue
<b>Patient ID</b> 011907160265		<b>Collection Date</b> 16/07/2019
<b>Specimen ID</b> MOLQ/B-1350/19		<b>Report Date</b> 24/07/2019

## SURGICAL PATHOLOGY REPORT

Gluteal lesion

### DIAGNOSIS

**Benign Mesenchymal Lesion.**



#### SPECIMEN

Gluteal lesion

#### GROSS

Received two grayish white tissue piece measuring 2x3.9cm.

#### Microscopy

- Section examined shows fibro collagenous tissue mature adipose cells granulation tissue. Section also shows mononuclear inflammatory cells, plasma cells macrophages, multinucleated giant cells polymorphs.

**Note :** All biopsy specimen will be stored for 15 (fifteen)days, block and slides for 5(five) years only from the time of receipt at the laboratory. No request ,for any of the above ,will be entertained after the due date.

#### Reference

- Rosai and Ackerman's Surgical Pathology.
- Modern Surgical Pathology.

**Gulshan Yadav, MD  
Consultant Pathologist**