

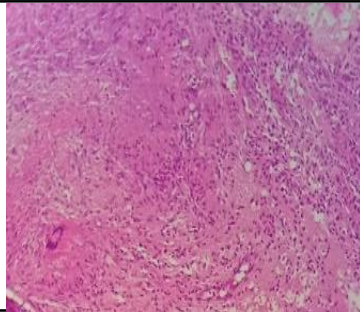
<b>Patient Name</b> Mr. SUHAIB RASHID/LAL CHOWK	<b>Client Name</b> Tantray Labs, Jammu & Kashmir	<b>Specimen Received</b> 11/07/2019
<b>Age/Sex</b> 22 Years/Male	<b>Client Code</b>	<b>Specimen Type</b> Tissue
<b>Patient ID</b> 011907110407	<b>Ref. Doctor</b>	<b>Collection Date</b> 11/07/2019
<b>Specimen ID</b> MOLQ/B-1318/19		<b>Report Date</b> 24/07/2019

## SURGICAL PATHOLOGY REPORT

Nap of neck

### DIAGNOSIS

**Granulomatous reaction**  
**(Tubercular pathology suspicious.)**



#### SPECIMEN

Nap of neck

#### GROSS

Received 1x1cm grayish white tissue piece.

#### Microscopy

1. Section examined shows fibro collagenous tissue multinucleated giant cells necrosis, epitheloid cells/histiocytes lymphocytes.

Mo malignant cells seen.

**Note :** All biopsy specimen will be stored for 15 (fifteen)days, block and slides for 5(five) years only from the time of receipt at the laboratory. No request ,for any of the above ,will be entertained after the due date.

#### Reference

- i) Rosai and Ackerman's Surgical Pathology.
- ii) Modern Surgical Pathology.

Gulsh  
Consi  
  
;ist