

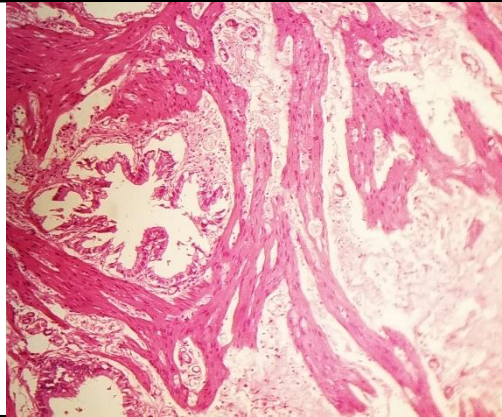
Patient Name	DILSHADA/P-CHOK	Client Name	A-One Collection Centre, Jammu & Kashmir	Specimen Received	19-Jul-2019
Age/Sex	35 Years/Female			Specimen Type	Tissue
Patient ID	041907190013			Collection Date	19-Jul-2019
Specimen ID	MOLQ/B-1377/19			Report Date	22-Jul-2019

SURGICAL PATHOLOGY REPORT

GALL BLADDER.

DIAGNOSIS

CHOLECYSTITIS AND CHOLELITHIASIS.



SPECIMEN

Gall Bladder.

GROSS

Received 5.5x2.5 cm long gall bladder. Cut section shows stones.

Microscopy

- Section examined shows ulcerative mucosa and Rokitansky-Aschoff sinuses (irregularly shaped tubular structures lined by cuboidal lining epithelium with round to oval nucleus) with fibro collagenous tissue and inflammatory cells (lymphocytes).

Note : All biopsy specimen will be stored for 15 (fifteen) days, block and slides for 5 (five) years only from the time of receipt at the laboratory. No request ,for any of the above will be entertained after the due date.

Reference

- Rosai and Ackerman's Surgical Pathology.
- Modern Surgical Pathology.

**Gulshan Yadav, MD
Consultant Pathologist**