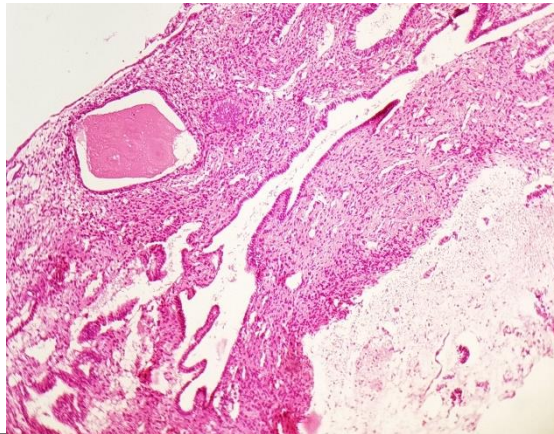


<b>Patient Name</b>	<b>Mrs. PUSHPA PANDE</b>	<b>Client Name</b>	SBS Diagnostic Centre,	<b>Specimen Received</b>	19-Jul-2019
<b>Age/Sex</b>	63 Years/Female		Gurgaon	<b>Specimen Type</b>	Tissue
<b>Patient ID</b>	011907190177			<b>Collection Date</b>	19-Jul-2019
<b>Specimen ID</b>	MOLQ/B-1381/19			<b>Report Date</b>	22-Jul-2019 9

## SURGICAL PATHOLOGY REPORT

### Endometrium

#### SIMPLE HYPERPLASIA WITHOUT ATYPIA



#### **SPECIMEN**

Endometrium

#### **GROSS**

Received multiple greyish white tissue piece.

#### **Microscopy**

1. Section examined shows small endometrial glands with cystically dilated glands revealing cuboidal lining epithelium and round to oval nucleus. Stroma shows mononuclear inflammatory cells.
2. No granuloma seen. No malignant cells seen.

**Note :** All biopsy specimen will be stored for 15 (fifteen) days, block and slides for 5 (five) years only from the time of receipt at the laboratory. No request for any of the above, will be entertained after the due date.

#### **Reference**

- i) Rosai and Ackerman's Surgical Pathology.
- ii) Modern Surgical Pathology.

**Gulshan Yadav, MD**  
**Consultant Pathologist**