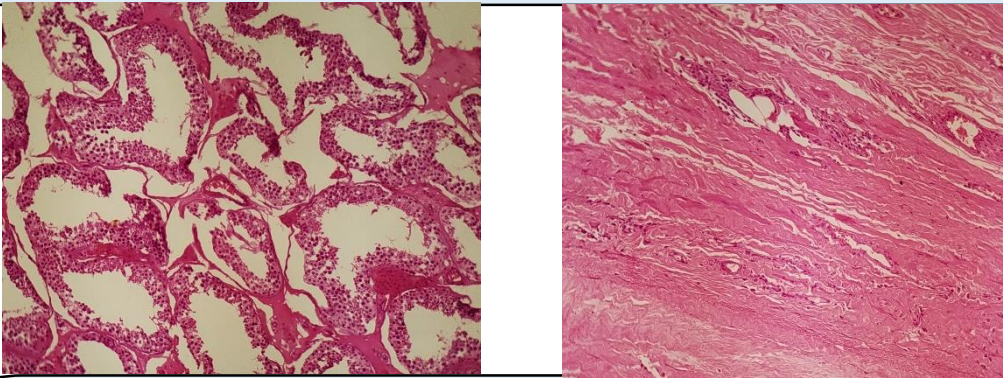


Patient Name	Mr. GH MOHIDEEN	Client Name	Patients Care Clinical Laboratory, Jammu & Kashmir	Specimen Received	12-Jul-2019
Age/Sex	65 Years/Male			Specimen Type	Tissue
Patient ID	011907110414			Collection Date	12-Jul-2019
Specimen ID	MOLQ/B-1327-19			Report Date	22-Jul-2019

SURGICAL PATHOLOGY REPORT
RIGHT TESTES WITH EPIDIDYMIS

DIAGNOSIS

HYDROCELE



SPECIMEN

RIGHT TESTES WITH EPIDIDYMIS

GROSS

Received 8X5.6 cm greyish white tissue piece. Cut section shows 3x3 cm testes surrounded with 4x5 cm surrounding membrane with straw colored fluid.

Microscopy

1. Section examined shows seminiferous tubules with immature and mature spermatogenic cells with epididymis which is unremarkable.
2. Hydrocele sac shows fibrocollagenous tissue, blood vessels and inflammatory cells.
3. No granuloma seen. No malignant cells seen.
4. **Note :** All biopsy specimen will be stored for 15 (fifteen)days, block and slides for 5(five) years only from the time of receipt at the laboratory. No request ,for any of the above ,will be entertained after the due date.

Reference

- i) Rosai and Ackerman's Surgical Pathology.
- ii) Modern Surgical Pathology.

Gulshan Yadav, MD
Consultant Pathologist