

<b>Patient Name</b>	<b>Mrs. MUFIDAN</b>	<b>Client Name</b>	Arban Hospital	<b>Specimen Received</b>	15-Jul-2019
<b>Age/Sex</b>	22 Years/Female		Opp. G.C. High School Patoudi Road,	<b>Specimen Type</b>	Tissue
<b>Patient ID</b>	011907150342		Tauru Distt. Nuh	<b>Collection Date</b>	15-Jul-2019
<b>Specimen ID</b>	MOLQ/B-1344/19	<b>Client Code</b>	MolQ1684P	<b>Report Date</b>	20-Jul-2019

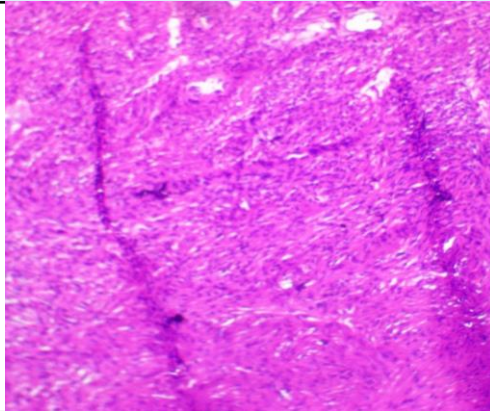
**SURGICAL PATHOLOGY REPORT**

**Ovarian cyst**

**DIAGNOSIS**

**Hemorrhagic cyst with simple cyst.**

**Kindly Co-relate clinically and radiologically**



**SPECIMEN**

Ovarian cyst

**GROSS**

Received 3.2x2.1cm grayish white tissue piece cut section shows blood clot.

**Microscopy**

Section examined shows ovarian tissue with blood clot no trophoblastic cells and no villi seen.

**Note :** All biopsy specimen will be stored for 15 (fifteen)days, block and slides for 5(five) years only from the time of receipt at the laboratory. No request ,for any of the above ,will be entertained after the due date.

**Reference**

- i) Rosai and Ackerman's Surgical Pathology.
- ii) Modern Surgical Pathology.

**Gulshan Yadav, MD  
Consultant Pathologist**