

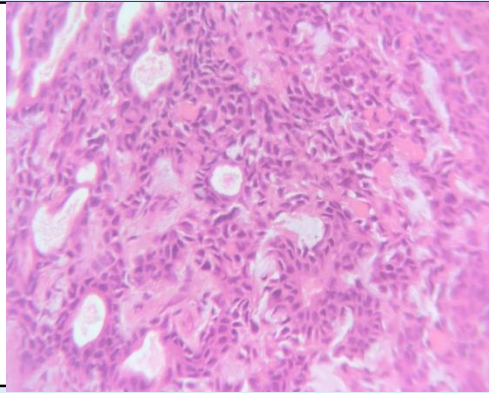
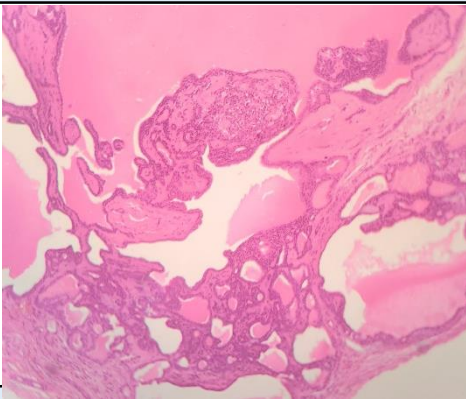
<b>Patient Name</b>	<b>Mr. VIJAY KUMAR GOUR</b>	<b>Client Name</b>	Sharma Health Solution Point, Gurgaon	<b>Specimen Received</b>	15-Jul-19
<b>Age/Sex</b>	28 Years/Male			<b>Specimen Type</b>	Slide
<b>Patient ID</b>	011907150017			<b>Collection Date</b>	15-Jul-19
<b>Specimen ID</b>	MOLQ/B-1342-19			<b>Report Date</b>	20-Jul-19

## SURGICAL PATHOLOGY REPORT

Cyst on Lower Lip

### DIAGNOSIS

## PLEOMORPHIC ADENOMA



#### SPECIMEN

Cyst on Lower Lip

#### GROSS

Received 1x0.5 cm greyish white tissue piece.

#### Microscopy

**Scanner view** revealed tumor mass with highly cellular areas.

**Low power view** revealed epithelial component formed by ducts and small cyst like spaces that contained abundant eosinophilic coagulum and arranged in small cellular nests, sheets of cells and anastomosing cords. Myoepithelial cells with variable morphology- spindle cells were also evident. Mesenchymal component was composed of fibrous and myxoid areas with endothelial lined blood capillaries of varying size and shape with RBCs.

**High power view** confirmed the above mentioned findings.

**Note :** All biopsy specimen will be stored for 15 (fifteen) days, block and slides for 5 (five) years only from the time of receipt at the laboratory. No request, for any of the above, will be entertained after the due date.

#### Reference

- i) Rosai and Ackerman's Surgical Pathology.
- ii) Modern Surgical Pathology.
- iii) Safers 7<sup>th</sup> edition

**Tina Bhardwaj, MDS**  
**Consultant Oral Histopathologist**

**Gulshan Yadav, MD**  
**Consultant Pathologist**