

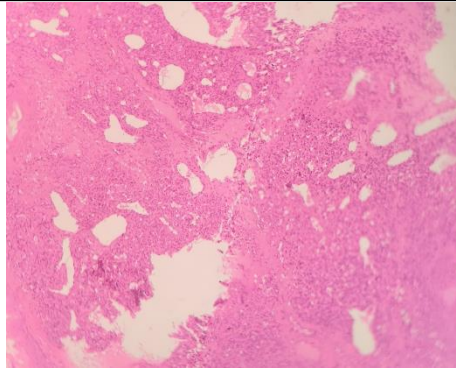
Patient Name	Mrs. PUSHPA	Client Name	S. S. Polyclinic,	Specimen Received	14-Jul-2019
Age/Sex	31 Years/Female		New Delhi	Specimen Type	Tissue
Patient ID	011907140065			Collection Date	14-Jul-2019
Specimen ID	MOLQ/B-1339-19			Report Date	20-Jul-2019

SURGICAL PATHOLOGY REPORT

Left Sided Nasal Mass

DIAGNOSIS

INFLAMMATORY POLYP



SPECIMEN

Left Sided Nasal Mass

GROSS

Received tiny grayish white tissue piece.

Microscopy

1. Section examined shows squamous lining epithelium with round nucleus. Deeper tissue shows fibrocollageneous tissue, inflammatory cells chiefly composed of lymphocytes, histiocytes, plasma cells and few polymorphs.
2. No granuloma and no malignant cells seen.

Note : All biopsy specimen will be stored for 15 (fifteen)days, block and slides for 5(five) years only from the time of receipt at the laboratory. No request ,for any of the above ,will be entertained after the due date.

Reference

- i) Rosai and Ackerman's Surgical Pathology.
- ii) Modern Surgical Pathology.

Gulshan Yadav, MD
Consultant Pathologist