

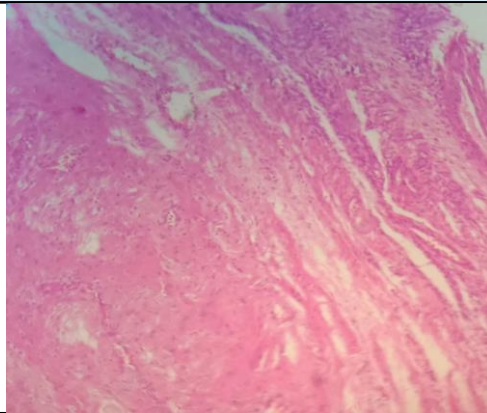
Patient Name	Miss. SNEHA	Client Name	Civil Hospital Sec-10	Specimen Received	15/07/2019
Age/Sex	19 YRS/F			Specimen Type	Tissue
Patient ID	011907150188			Collection Date	15/07/2019
Specimen ID	MOLQ/B-1343/19			Report Date	18/07/2019

SURGICAL PATHOLOGY REPORT

Ovarian cyst

DIAGNOSIS

Dermoid cyst



SPECIMEN

Ovarian cyst

GROSS

Received 6x6.5cm greyish white tissue piece cut section shows cheese material.

Microscopy

- Section examined shows
Squamous lining epithelium, blood vessels, keratin flakes and glands.

Note : All biopsy specimen will be stored for 15 (fifteen)days, block and slides for 5(five) years only from the time of receipt at the laboratory. No request ,for any of the above ,will be entertained after the due date.

Reference

- Rosai and Ackerman's Surgical Pathology.
- Modern Surgical Pathology.

**Gulshan Yadav, MD
Consultant Pathologist**