

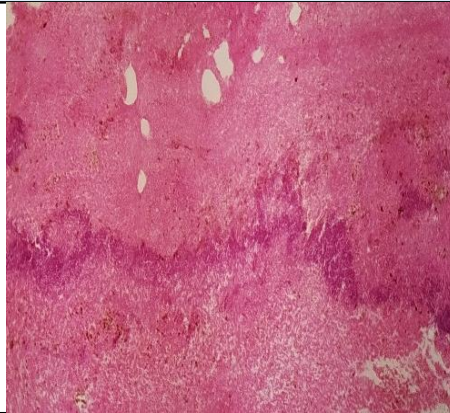
Patient Name	Mrs. SHAKUNTLA-34676	Client Name	Pushpanjali Hospital	Specimen Received	14/07/2019
Age/Sex	48 YRS/F		(Rewari)	Specimen Type	Tissue
Patient ID	011907140241			Collection Date	14/07/2019
Specimen ID	MOLQ/B-1341/19			Report Date	18/07/2019

SURGICAL PATHOLOGY REPORT

Endometrium

DIAGNOSIS

Kindly Co-relate clinically and radiologically.



SPECIMEN

Endometrium

GROSS

Received multiple grayish white tissue piece.

Microscopy

- Section examined shows predominantly endocervical glands with stromal cells, blood vessels. Only occasional broken endometrial glands seen with small round nucleus in sample received.

Note : All biopsy specimen will be stored for 15 (fifteen)days, block and slides for 5(five) years only from the time of receipt at the laboratory. No request ,for any of the above ,will be entertained after the due date.

Reference

- Rosai and Ackerman's Surgical Pathology.
- Modern Surgical Pathology.

Gulshan Yadav, MD
Consultant Pathologist