

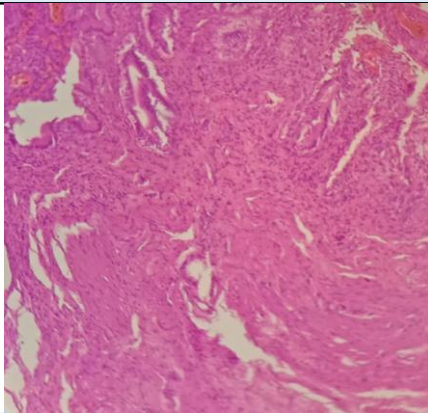
Patient Name	Mrs. PRATIBHA PALIWAL	Client Name	Uttam Diagnostics, Agra	Specimen Received	14/07/2019
9829Age/Sex	50 Years/Female			Specimen Type	Tissue
Patient ID	011907140020			Collection Date	14/07/2019
Specimen ID	MOLQ/B-1338/19			Report Date	17/07/2019

SURGICAL PATHOLOGY REPORT

Gall Bladder

DIAGNOSIS

CHOLECYSTITIS AND CHOLELITHIASIS.



SPECIMEN

Gall Bladder

GROSS

Received 5x2.5cm long gall bladder already cut open with stones.

Microscopy

- Section examined shows ulcerative mucosa and Rokitansky Aschoff sinuses (irregularly shaped tubular structures lined by cuboidal lining epithelium with round to oval nucleus) with fibrocollagenous tissue and inflammatory cells (lymphocytes).

Note : All biopsy specimen will be stored for 15 (fifteen) days, block and slides for 5 (five) years only from the time of receipt at the laboratory. No request, for any of the above, will be entertained after the due date.

Reference

- Rosai and Ackerman's Surgical Pathology.
- Modern Surgical Pathology.

Gulshan Yadav, MD
Consultant Pathologist