

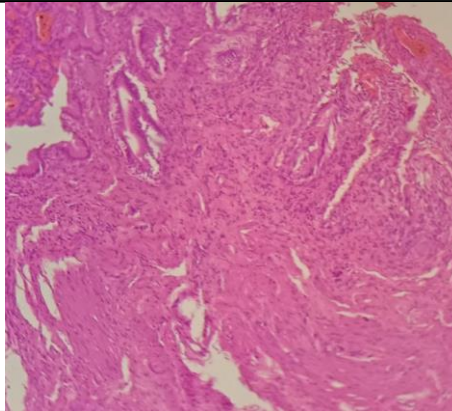
<b>Patient Name</b>	<b>Ms. MAHTABA</b>	<b>Client Name</b>	Patients Care Clinical	<b>Specimen Received</b>	13/07/2019
<b>9829Age/Sex</b>	60 Years/Female		Laboratory, Jammu & Kashmir	<b>Specimen Type</b>	Tissue
<b>Patient ID</b>	011907130375			<b>Collection Date</b>	13/07/2019
<b>Specimen ID</b>	MOLQ/B-1336/19			<b>Report Date</b>	17/07/2019

## SURGICAL PATHOLOGY REPORT

Gall Bladder

### DIAGNOSIS

**CHOLECYSTITIS**



#### SPECIMEN

Gall Bladder

#### GROSS

Received 5.8x2cm cm long gall bladder already cut open no stones.

#### Microscopy

- Section examined shows ulcerative mucosa and Rokitansky-Aschoff sinuses (irregularly shaped tubular structures lined by cuboidal lining epithelium with round to oval nucleus) with fibrocollagenous tissue and inflammatory cells (lymphocytes).

**Note :** All biopsy specimen will be stored for 15 (fifteen) days, block and slides for 5 (five) years only from the time of receipt at the laboratory. No request, for any of the above, will be entertained after the due date.

#### Reference

- Rosai and Ackerman's Surgical Pathology.
- Modern Surgical Pathology.

**Gulshan Yadav, MD**  
Consultant Pathologist