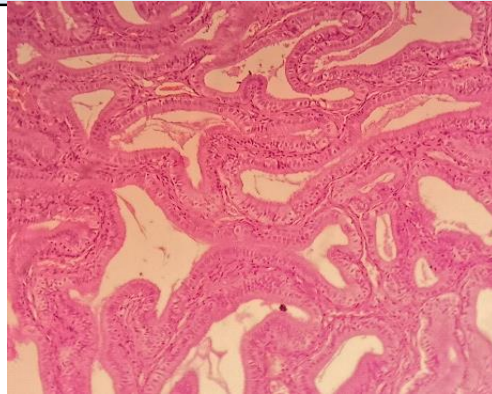


Patient Name	MEHBOBA W/O JOHN MOHMAD	Client	Patients Care Clinical Laboratory, Jammu & Kashmir	Specimen Received	12/07/19
Age/Sex	30 Years/Male			Specimen Type	Tissue
Patient ID	011907110413			Collection Date	12/07/19
Specimen ID	MOLQ/B-1326/19			Report Date	16/07/19

SURGICAL PATHOLOGY REPORT Gall Bladder

DIAGNOSIS

CHOLECYSTITIS.



SPECIMEN
Gall Bladder

GROSS
Received 8x2.3cm long gall bladder. Cut section shows no stones.


Microscopy

Section examined shows ulcerative mucosa and Rokitansky-Aschoff sinus (irregularly shaped tubular structures lined by cuboidal lining epithelium with round to oval nucleus) with fibrocollagenous tissue and inflammatory cells (lymphocytes).

Note : All biopsy specimen will be stored for 15 (fifteen) days, block and slides for 5 (five) years only from the time of receipt at the laboratory. No request, for any of the above, will be entertained after the due date.

Reference

- i) Rosai and Ackerman's Surgical Pathology.
- ii) Modern Surgical Pathology.


Gulshan Yadav, MD
Consultant Pathologist