

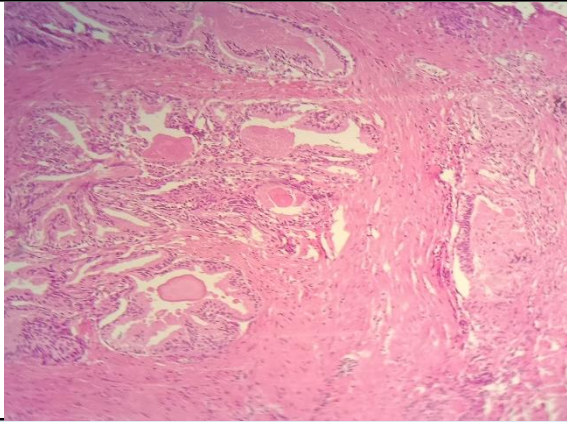
Patient Name	SATYA PRKASH	Client Name	Uttam Diagnostics, Agra,	Specimen Received	12/07/19
Age/Sex	66 YRS/M		Tauru	Specimen Type	Tissue
Patient ID	011907120007			Collection Date	12/07/19
Specimen ID	MOLQ/B-1316/19			Report Date	15/07/19

SURGICAL PATHOLOGY REPORT

Prostate chips

DIAGNOSIS

BENIGN PROSTATIC HYPERPLASIA



SPECIMEN

Prostate chips

GROSS

Received multiple grayish white tissue piece, 5x6 cm in aggregate.

Microscopy

Section examined shows bilayered prostatic glands with columnar lining epithelium and with small round to oval nucleus surrounded by large number of fibrocollagenous tissue and mononuclear inflammatory cell.

No granuloma seen. No malignant cells seen.

Note : All biopsy specimen will be stored for 15 (fifteen)days, block and slides for 5(five) years only from the time of receipt at the laboratory. No request ,for any of the above ,will be entertained after the due date.

Reference

- i) Rosai and Ackerman's Surgical Pathology.
- ii) Modern Surgical Pathology.

Gulshan Yadav, MD
Consultant Pathologist