

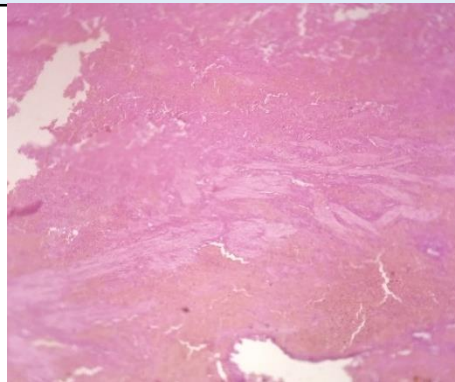
Patient Name	Ms. FATIMA 9803	Client Name	Patients Care Clinical Laboratory, Jammu & Kashmir)	Specimen Received	12-Jul-2019
Age/Sex	21 Years/Female			Specimen Type	Tissue
Patient ID	011907110412			Collection Date	12-Jul-2019
Specimen ID	MOLQ/B-1324/19			Report Date	15-Jul-2019

SURGICAL PATHOLOGY REPORT

Gall Bladder

DIAGNOSIS

CHOLECYSTITIS AND CHOLELITHIASIS.



SPECIMEN

Gall Bladder

GROSS

Received 6x1.8cm long gall bladder. Cut section shows stones.

Microscopy

Section examined shows ulcerative mucosa and Rokitansky-Aschoff sinuses (irregularly shaped tubular structures lined by cuboidal lining epithelium with round to oval nucleus) with fibro collagenous tissue and inflammatory cells (lymphocytes).

Note : All biopsy specimen will be stored for 15 (fifteen) days, block and slides for 5 (five) years only from the time of receipt at the laboratory. No request, for any of the above, will be entertained after the due date.

Reference

- i) Rosai and Ackerman's Surgical Pathology.
- ii) Modern Surgical Pathology.

Gulshan Yadav, MD
Consultant Pathologist