

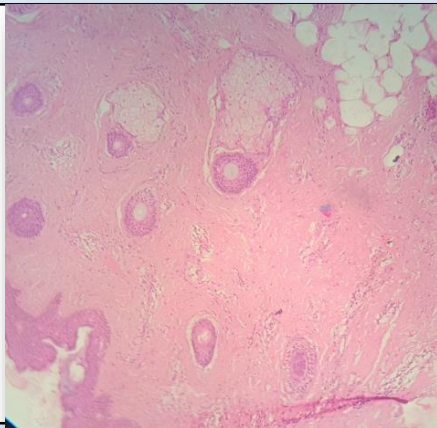
Patient Name	HAME CHAND	Client Name	Sona Devi Hospital	Specimen Received	10/07/19
Age/Sex	35 YRS/M			Specimen Type	Tissue
Patient ID	011907100155			Collection Date	10/07/19
Specimen ID	MOLQ/B-1304/19			Report Date	15/07/19

SURGICAL PATHOLOGY REPORT

Sebaceous cyst

DIAGNOSIS

Sebaceous cyst.



SPECIMEN

Sebaceous cyst

GROSS

Received multiple grayish white tissue piece.


Microscopy

Section examined shows squamous lining epithelium hyperkeratosis, parakeratosis and keratin flakes.

Note : All biopsy specimen will be stored for 15 (fifteen) days, block and slides for 5 (five) years only from the time of receipt at the laboratory. No request, for any of the above, will be entertained after the due date.

Reference

- i) Rosai and Ackerman's Surgical Pathology.
- ii) Modern Surgical Pathology.


Gulshan Yadav, MD
Consultant Pathologist