

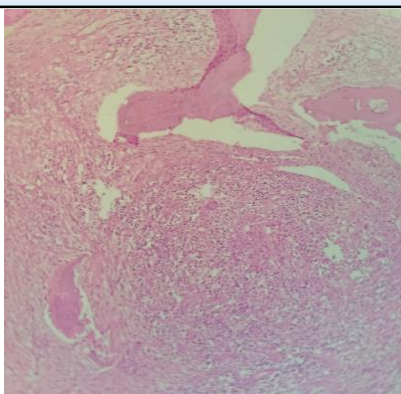
Patient Name Mr. MANI RAM SAINI-34009	Client Name PushpanjaliHospital	Specimen Received	08/07/19
Age/Sex 55 Years/Male	(Rewari)	Specimen Type	Tissue
Patient ID 011907080278		Collection Date	08/07/19
Specimen ID MOLQ/B-1295/19		Report Date	15/07/19

SURGICAL PATHOLOGY REPORT

Metatarsal

DIAGNOSIS

Chronic Osteomyelitis



SPECIMEN

Metatarsal

GROSS

Received 5x1.5cm bony tissue piece.

Microscopy

Section examined shows bony trabeculae, fibro collagenous tissue, blood vessels, Sequestrum with histiocytes and plasma cells.

Note : All biopsy specimen will be stored for 15 (fifteen) days, block and slides for 5 (five) years only from the time of receipt at the laboratory. No request, for any of the above, will be entertained after the due date.

Reference

- i) Rosai and Ackerman's Surgical Pathology.
- ii) Modern Surgical Pathology.

Gulshan Yadav, MD
Consultant Pathologist