

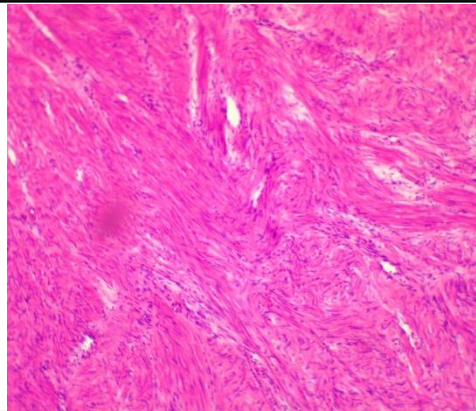
<b>Patient Name</b>	BISANI 33569	<b>Client Name</b>	Pushpanjali Hospital (Rewari)	<b>Specimen Received</b>	08/07/2019
<b>Age/Sex</b>	53 YRS/F			<b>Specimen Type</b>	Tissue
<b>Patient ID</b>	011907080287			<b>Collection Date</b>	08/07/2019
<b>Specimen ID</b>	MOLQ/B-1297/19			<b>Report Date</b>	12/07/2019

## SURGICAL PATHOLOGY REPORT

Uterus with Cervix

### DIAGNOSIS

**Leiomyoma**



#### SPECIMEN

Uterus with Cervix

#### GROSS

Received 12x9.5 cm uterus with cervix with bilateral tube. Cut section shows multiple fibroid measuring 6x5,2x1.8cm.

#### Microscopy

1. Section examined shows
  - 1)Endometrium with proliferative phase
  - 2)Myometrium with muscle bundles
  - 3)Cervix with mononuclear inflammatory cells
  - 4)Fibroid with interlacing muscle bundles
  - 5)Bilateral tuber unremarkable

**Note :** All biopsy specimen will be stored for 15 (fifteen)days, block and slides for 5(five) years only from the time of receipt at the laboratory. No request ,for any of the above ,will be entertained after the due date.

#### Reference

- i) Rosai and Ackerman's Surgical Pathology.
- ii) Modern Surgical Pathology.

**Gulshan Yadav, MD**  
Consultant Pathologist