

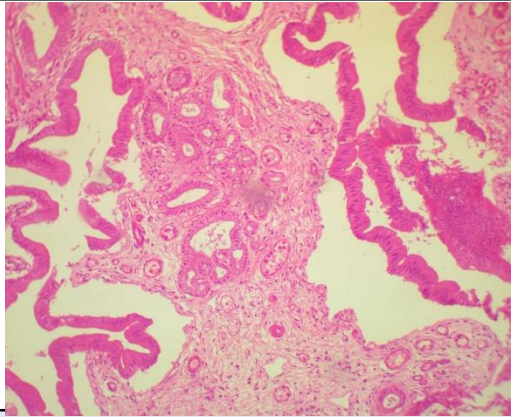
<b>Patient Name</b>	BISANI 33569	<b>Client Name</b>	Pushpanjali Hospital (Rewari)	<b>Specimen Received</b>	08/07/2019
<b>Age/Sex</b>	53 YRS/F			<b>Specimen Type</b>	Tissue
<b>Patient ID</b>	011907080284			<b>Collection Date</b>	08/07/2019
<b>Specimen ID</b>	MOLQ/B-1296/19			<b>Report Date</b>	12/07/2019

## SURGICAL PATHOLOGY REPORT

### Gall Bladder

#### DIAGNOSIS

**CHOLECYSTITIS AND CHOLELITHIASIS.**



#### SPECIMEN

Gall Bladder

#### GROSS

Received 6x2.3 cm long gall bladder. Cut section shows stones.

#### Microscopy

- Section examined shows ulcerative mucosa and Rokitansky-Aschoff sinuses (irregularly shaped tubular structures lined by cuboidal lining epithelium with round to oval nucleus) with fibrocollagenous tissue and inflammatory cells (lymphocytes).

**Note :** All biopsy specimen will be stored for 15 (fifteen) days, block and slides for 5 (five) years only from the time of receipt at the laboratory. No request, for any of the above, will be entertained after the due date.

#### Reference

- Rosai and Ackerman's Surgical Pathology.
- Modern Surgical Pathology.

**Gulshan Yadav, MD  
Consultant Pathologist**