

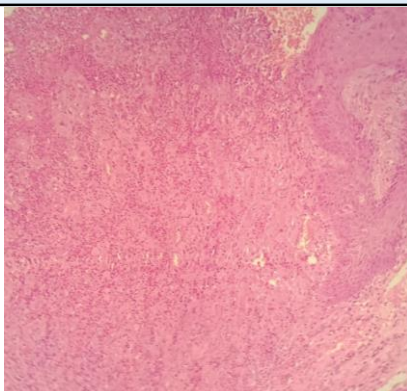
Patient Name	Mr. DINESH	Client Name	Prakash Hospital	Specimen Received	07/07/19
Age/Sex	47 YRS/M			Specimen Type	Tissue
Patient ID	011907070165			Collection Date	07/07/19
Specimen ID	MOLQ/B-1288/19			Report Date	11/07/19

SURGICAL PATHOLOGY REPORT

Ulcer on the right ventral surface of the tongue.

DIAGNOSIS

Irritational Fibroma (Inflammed)



SPECIMEN

Ulcer on the right ventral surface of the tongue.

GROSS

Ulcer on the right ventral surface of the tongue.

Microscopy

Section examined shows stratified squamous lining epithelium with round to oval nucleus and long and slender (few fused to each other) rete pegs overlying the connective tissue stroma. Stroma reveals bundles of collagen fibers interspersed with plump fibroblasts and fibrocytes. Presence of dense and diffuse inflammatory infiltrate present in the deeper part of stroma chiefly composed of neutrophils, lymphocytes, eosinophils and plasma cells. Numerous endothelial lined blood capillaries filled with RBCs are also evident.

Note : All biopsy specimen will be stored for 15 (fifteen) days, block and slides for 5 (five) years only from the time of receipt at the laboratory. No request, for any of the above, will be entertained after the due date.

Reference

- i) Rosai and Ackerman's Surgical Pathology.
- ii) Modern Surgical Pathology.

Gulshan Yadav, MD
Consultant Pathologist