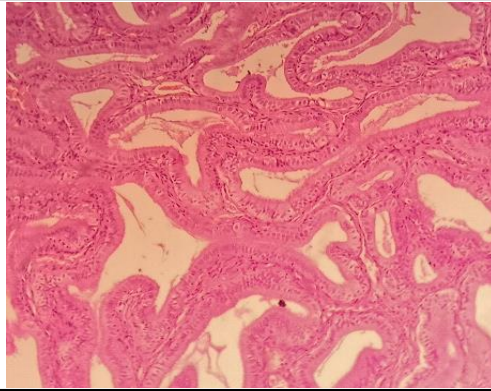


Patient Name	MEHBOBA W/O JOHN MOHMAD	Client	A-One Collection Centre, Jammu & Kashmir	Specimen Received	04/07/19
Age/Sex	40 YRS/F			Specimen Type	Tissue
Patient ID	041907040008			Collection Date	04/07/19
Specimen ID	MOLQ/B-1269/19			Report Date	09/07/19

SURGICAL PATHOLOGY REPORT Gall Bladder

DIAGNOSIS

CHOLECYSTITIS.



SPECIMEN

Gall Bladder

GROSS

Received 6x3.8cm cm long gall bladder already cut open without stones.


Microscopy

Section examined shows ulcerative mucosa and Rokitansky-Aschoff sinuses (irregularly shaped tubular structures lined by cuboidal lining epithelium with round to oval nucleus) with fibrocollagenous tissue and inflammatory cells (lymphocytes).

Note : All biopsy specimen will be stored for 15 (fifteen) days, block and slides for 5 (five) years only from the time of receipt at the laboratory. No request, for any of the above, will be entertained after the due date.

Reference

- Rosai and Ackerman's Surgical Pathology.
- Modern Surgical Pathology.


Gulshan Yadav, MD
Consultant Pathologist