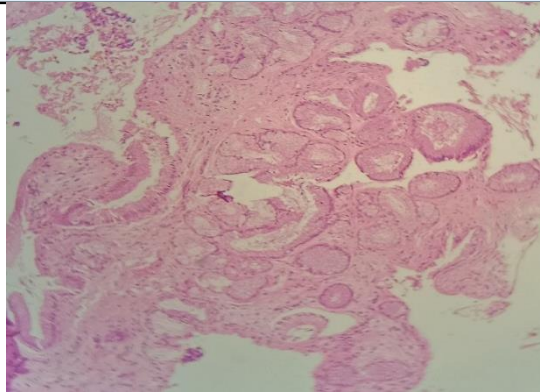


<b>Patient Name</b>	NASIR ALI/TRAL	<b>Client</b>	A-One Collection Centre, Jammu & Kashmir	<b>Specimen Received</b>	04/07/19
<b>Age/Sex</b>	28 YRS/M			<b>Specimen Type</b>	Tissue
<b>Patient ID</b>	041907040007			<b>Collection Date</b>	04/07/19
<b>Specimen ID</b>	MOLQ/B-1270/19			<b>Report Date</b>	09/07/19

## SURGICAL PATHOLOGY REPORT Gall Bladder

### DIAGNOSIS

### CHOLECYSTITIS.



**SPECIMEN**  
Gall Bladder

**GROSS**  
Received 6.6x2.9 cm long gall bladder without stones.


#### Microscopy

Section examined shows ulcerative mucosa and Rokitansky-Aschoff sinuses (irregularly shaped tubular structures lined by cuboidal lining epithelium with round to oval nucleus) with fibrocollagenous tissue and inflammatory cells (lymphocytes).

**Note :** All biopsy specimen will be stored for 15 (fifteen) days, block and slides for 5 (five) years only from the time of receipt at the laboratory. No request, for any of the above, will be entertained after the due date.

#### Reference

- i) Rosai and Ackerman's Surgical Pathology.
- ii) Modern Surgical Pathology.

  
**Gulshan Yadav, MD**  
**Consultant Pathologist**