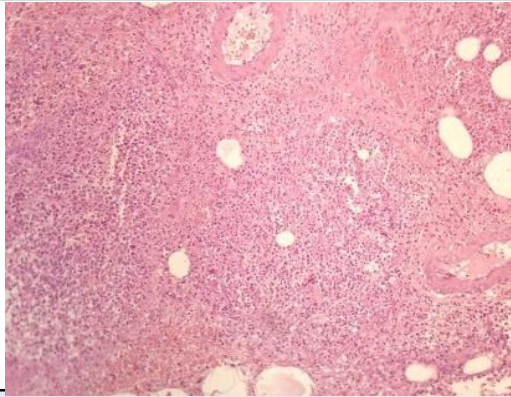


<b>Patient Name</b>	GOLA	<b>Client</b>	Accurate Path (C), Agra	<b>Specimen Received</b>	06/07/19
<b>Age/Sex</b>	22 YRS/M			<b>Specimen Type</b>	Tissue
<b>Patient ID</b>	011907060009			<b>Collection Date</b>	06/07/19
<b>Specimen ID</b>	MOLQ/B-1279/19			<b>Report Date</b>	09/07/19

**SURGICAL PATHOLOGY REPORT**  
**Appendix**

**DIAGNOSIS**

**ACUTE APPENDICITIS**



**SPECIMEN**  
Appendix

**GROSS**  
Received 4x1.8cm long appendix. Cut section shows feco-lith.


**Microscopy**

Section examined shows lymphoid follicles with ulcerative mucosa. Deeper tissue shows inflammatory cells (polymorphs and lymphocytes). No granuloma seen. No malignant cells seen.

**Note :** All biopsy specimen will be stored for 15 (fifteen)days, block and slides for 5(five) years only from the time of receipt at the laboratory. No request ,for any of the above ,will be entertained after the due date.

**Reference**

- i) Rosai and Ackerman's Surgical Pathology.
- ii) Modern Surgical Pathology.

  
**Gulshan Yadav, MD**  
**Consultant Pathologist**