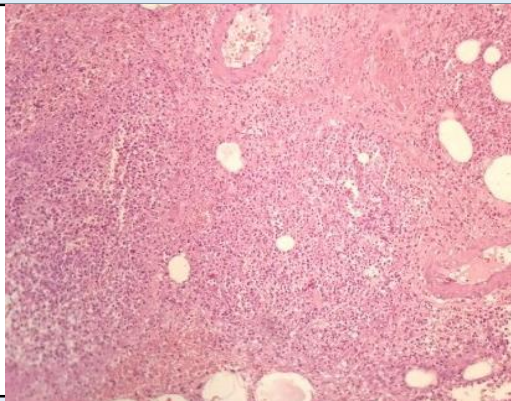


Patient Name	Ms. SEEMA 34010	Client	Pushpanjali Hospital (Rewari)	Specimen Received	04/07/19
Age/Sex	20 Years/Female			Specimen Type	Tissue
Patient ID	011907040196			Collection Date	04/07/19
Specimen ID	MOLQ/B-1266/19 (1)			Report Date	08/07/19

SURGICAL PATHOLOGY REPORT Appendix

DIAGNOSIS

ACUTE APPENDICITIS



SPECIMEN

Appendix

GROSS

Received 4x1.1cm long appendix. Cut section shows feco-lith.

Microscopy

Section examined shows lymphoid follicles with ulcerative mucosa. Deeper tissue shows inflammatory cells (polymorphs and lymphocytes). No granuloma seen. No malignant cells seen.

Note : All biopsy specimen will be stored for 15 (fifteen)days, block and slides for 5(five) years only from the time of receipt at the laboratory. No request ,for any of the above ,will be entertained after the due date.

Reference

- i) Rosai and Ackerman's Surgical Pathology.
- ii) Modern Surgical Pathology.

Gulshan Yadav, MD
Consultant Pathologist