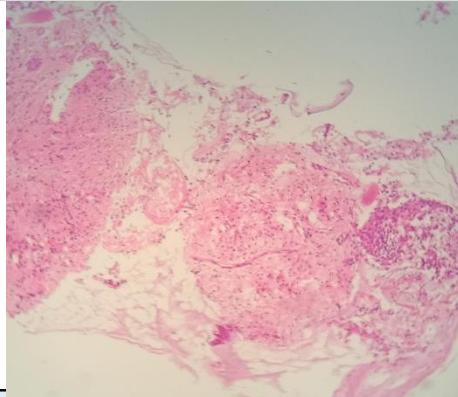


Patient Name	RAJA BUGUN/QUAZIGUND	Client Name	Haseeb Clinical Lab, Jammu & Kashmir	Specimen Received	02/07/19
Age/Sex	70 YRS/F			Specimen Type	Tissue
Patient ID	011907020466			Collection Date	02/07/19
Specimen ID	MOLQ/B-1254/19			Report Date	05/07/19

SURGICAL PATHOLOGY REPORT Endometrium

DIAGNOSIS

PROLIFERATIVE PHASE



SPECIMEN

Endometrium

GROSS

Received multiple grayish white tissue piece.

Microscopy

Section examined shows scanty tissue with occasional endometrial glands with cuboidal lining epithelium with round to oval nucleus. Surrounded by inflammatory cells.
No granuloma and no malignant cells in sample provide.

Note : All biopsy specimen will be stored for 15 (fifteen)days, block and slides for 5(five) years only from the time of receipt at the laboratory. No request ,for any of the above ,will be entertained after the due date.

Reference

- i) Rosai and Ackerman's Surgical Pathology.
- ii) Modern Surgical Pathology.



Gulshan Yadav, MD
Consultant Pathologist