

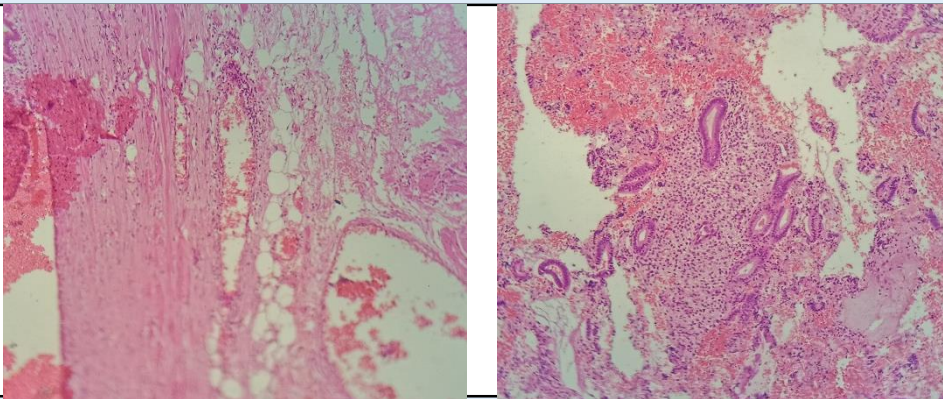
<b>Patient Name</b>	SATYA WATI	<b>Client Name</b>	SRG Hospital, Kotla Vihar	<b>Specimen Received</b>	02/07/19
<b>Age/Sex</b>	43 YRS/F			<b>Specimen Type</b>	Tissue
<b>Patient ID</b>	011907020289			<b>Collection Date</b>	02/07/19
<b>Specimen ID</b>	MOLQ/B-1253/19			<b>Report Date</b>	05/07/19

## SURGICAL PATHOLOGY REPORT

- (1) Tubo ovarian mass  
(2) Endometrium

### DIAGNOSIS

- (1) Ectopic pregnancy.**  
**(2) Bleeding endometrium.**



#### SPECIMEN

- (1) Tubo ovarian mass  
(2) Endometrium

#### GROSS

- (1) Received 4.5x2.2cm tubular tissue piece cut section shows blood clot.  
(2) Received multiple greyish white tissue piece.


#### Microscopy

- (1) Section examined shows surrounding tissue with large blood clot and trophoblastic cells.  
(2) Section examined shows small and tortuous endometrial glands with cuboidal to columnar lining epithelium having round to oval nucleus, Surrounded by stromal cells, fibrin and RBCs.

**Note :** All biopsy specimen will be stored for 15 (fifteen) days, block and slides for 5 (five) years only from the time of receipt at the laboratory. No request, for any of the above, will be entertained after the due date.

#### Reference

- i) Rosai and Ackerman's Surgical Pathology.  
ii) Modern Surgical Pathology.

  
**Gulshan Yadav, MD**  
Consultant Pathologist