

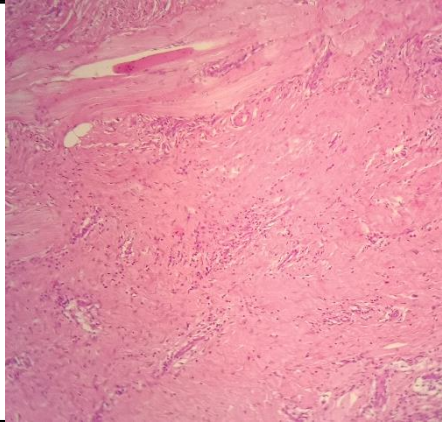
Patient Name SHARMA	Mrs. RENU	Client Name Uttam Diagnostics, Agra	Specimen Received Specimen Type	02/07/19 Tissue
Age/Sex	34 Years/Female		Collection Date	02/07/19
Patient ID	011907020007		Report Date	05/07/19
Specimen ID	MOLQ/B-1248/19			

SURGICAL PATHOLOGY REPORT

Cyst for upper elbow

DIAGNOSIS

Chronic infective lesion.
(Parasitic infestation to be ruled out)



SPECIMEN

Cyst for upper elbow

GROSS

Received multiple grayish white tissue piece, 4x5 cm in aggregate.


Microscopy

Section examined shows muscle bundles, fibro collagenous tissue mature adipose cells. Granulation tissue, multinucleated giant cells (histiocytes, lymphocytes) section also shows eosinophil. NO granuloma no malignant cells seen.

Note : All biopsy specimen will be stored for 15 (fifteen) days, block and slides for 5 (five) years only from the time of receipt at the laboratory. No request, for any of the above, will be entertained after the due date.

Reference

- i) Rosai and Ackerman's Surgical Pathology.
- ii) Modern Surgical Pathology.


Gulshan Yadav, MD
Consultant Pathologist