

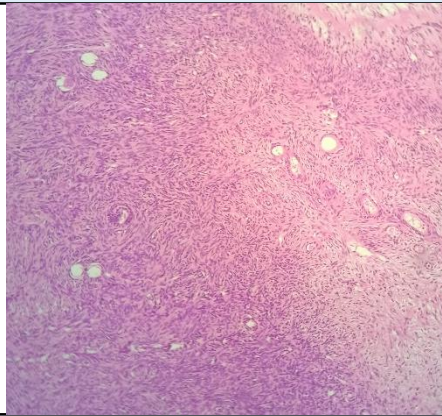
<b>Patient Name</b>	<b>Mrs. BABITA</b>	<b>Client Name</b>	Nisha Diagnostic Centre	<b>Specimen Received</b>	25-Jun-2019
<b>Age/Sex</b>	26 Years/Female			<b>Specimen Type</b>	Tissue
<b>Patient ID</b>	011906250216			<b>Collection Date</b>	25-Jun-2019
<b>Specimen ID</b>	MOLQ/B-1197/19			<b>Report Date</b>	<b>03 june 2019</b>

## SURGICAL PATHOLOGY REPORT

Bilateral ovary and tube

### DIAGNOSIS

Granulomatous reaction  
(Tubercular pathology with Hemorrhagic cyst ? endometriotic cyst.)



#### SPECIMEN

Bilateral ovary and tube

#### GROSS

Received bilateral ovary and tube measuring 2x2cm and 3x3cm with attached fat in single container.

#### Microscopy

Section examined from ovary shows ovarian tissue, RBCs, hemosiderin laden macrophages. Section from tube shows tubal lining epithelium with epitheloid cells granuloma with kegeous necrosis. Other ovary shows simple cyst.

**Note :** All biopsy specimen will be stored for 15 (fifteen)days, block and slides for 5(five) years only from the time of receipt at the laboratory. No request ,for any of the above ,will be entertained after the due date.

#### Reference

- i) Rosai and Ackerman's Surgical Pathology.
- ii) Modern Surgical Pathology.

**Gulshan Yadav, MD**  
Consultant Pathologist