

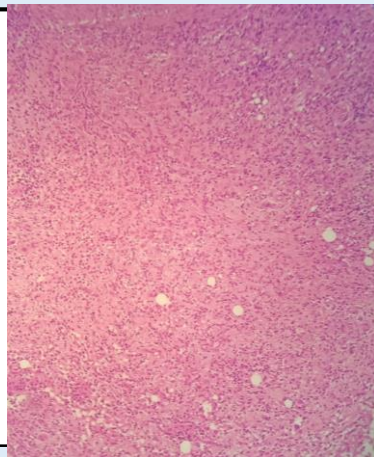
Patient Name	Mr. ABHINASH	Client	Polaris Hospital	Specimen Received	27/06/2019
Age/Sex	16 Years/Male			Specimen Type	Tissue
Patient ID	011906270399			Collection Date	27/06/2019
Specimen ID	MOLQ/B-1211/19			Report Date	03/07/2019

SURGICAL PATHOLOGY REPORT

foreign body granuloma.

DIAGNOSIS

Foreign body granuloma



SPECIMEN

foreign body granuloma.

GROSS

Received 1x1cm grayish white tissue piece.

Microscopy

Section examined shows

mature adipose cells, fibro collagenous tissue, blood vessels with large number of inflammatory cells Lymphocytes, plasma cells, histiocytes with multinucleated giant cells.

No granuloma and no malignant cells seen.

Note : All biopsy specimen will be stored for 15 (fifteen) days, block and slides for 5 (five) years only from the time of receipt at the laboratory. No request, for any of the above, will be entertained after the due date.

Reference

- i) Rosai and Ackerman's Surgical Pathology.
- ii) Modern Surgical Pathology.

Gulshan Yadav, MD
Consultant Pathologist