

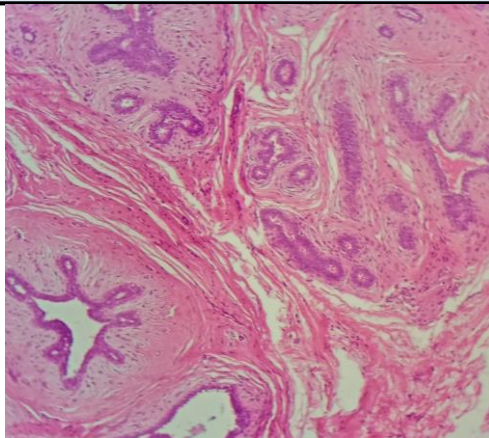
Patient Name	Ms. SUNITA 33604	Client	Pushpanjali	Specimen Received	27/06/2019
Age/Sex	32 Years/Female	Hospital (Rewari)		Specimen Type	Tissue
Patient ID	011906270313			Collection Date	27/06/2019
Specimen ID	MOLQ/B-1208/19			Report Date	03/07/2019

SURGICAL PATHOLOGY REPORT

Left breast Fibroadenoma

DIAGNOSIS

Benign Breast Lesion



SPECIMEN

Left breast Fibroadenoma

GROSS

Received 2.8x2.6cm grayish white tissue.

Microscopy

1. Section examined shows ducts with cuboidal epithelium with small round nucleus surrounded by fibro collagenous tissue. No granuloma seen. No malignant cells seen.

Note : All biopsy specimen will be stored for 15 (fifteen) days, block and slides for 5 (five) years only from the time of receipt at the laboratory. No request, for any of the above, will be entertained after the due date.

Reference

- i) Rosai and Ackerman's Surgical Pathology.
- ii) Modern Surgical Pathology.

Gulshan Yadav, MD
Consultant Pathologist