

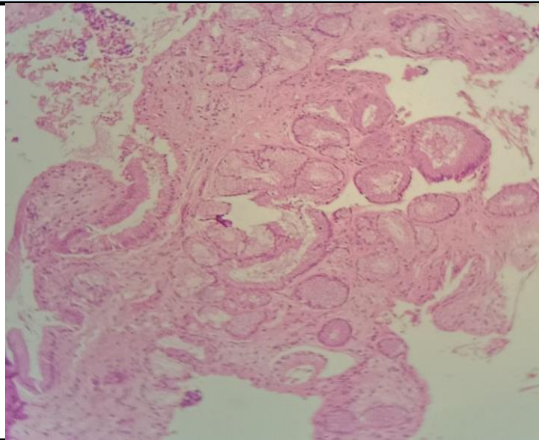
Patient Name 654 ZANGLI	Ms. MEEMA BEGAM	Client Apollo Laboratories CC, Jammu & Kashmir	Specimen Received Specimen Type	26/06/2019 Tissue
Age/Sex	35 Years/Female	Ordering Physician PROF G M SHEIKH MS	Collection Date	26/06/2019
Patient ID	011906260371	.	Report Date	03/07/2019
Specimen ID	MOLQ/B-1204/19			

SURGICAL PATHOLOGY REPORT

Gall Bladder

DIAGNOSIS

CHOLECYSTITIS AND CHOLELITHIASIS.



SPECIMEN

Gall Bladder

GROSS

Received 6.2x3 long gall bladder already cut open with tiny stones.

Microscopy

- Section examined shows ulcerative mucosa and Rokitansky-Aschoff sinuses (irregularly shaped tubular structures lined by cuboidal lining epithelium with round to oval nucleus) with fibro collagenous tissue and inflammatory cells (lymphocytes).

Note : All biopsy specimen will be stored for 15 (fifteen) days, block and slides for 5 (five) years only from the time of receipt at the laboratory. No request, for any of the above, will be entertained after the due date.

Reference

- Rosai and Ackerman's Surgical Pathology.
- Modern Surgical Pathology.

Gulshan Yadav, MD
Consultant Pathologist