

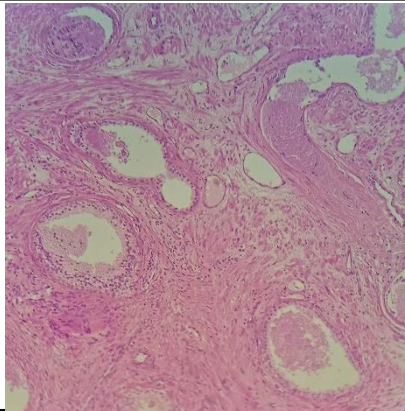
Patient Name	SURENDRA	Client Name	Accurate Path (C), Agra	Specimen Received	25-Jun-2019
Age/Sex	80 YRS/M			Specimen Type	Tissue
Patient ID	011906250011	ReferBy	DR.H.B. GUPTA	Collection Date	25-Jun-2019
Specimen ID	MOLQ/B-1191/19			Report Date	03-jul-2019

SURGICAL PATHOLOGY REPORT

Prostate

DIAGNOSIS

BENIGN PROSTATIC HYPERPLASIA



SPECIMEN

Prostate

GROSS

Received multiple grayish white tissue piece 2x3cm in aggregate.

Microscopy

Section examined shows bilayered prostatic glands with columnar lining epithelium and with small round to oval nucleus surrounded by large number of fibrocollagenous tissue and mononuclear inflammatory cell.

No granuloma seen. No malignant cells seen.

Note : All biopsy specimen will be stored for 15 (fifteen) days, block and slides for 5 (five) years only from the time of receipt at the laboratory. No request, for any of the above, will be entertained after the due date.

Reference

- i) Rosai and Ackerman's Surgical Pathology.
- ii) Modern Surgical Pathology.

Gulshan Yadav, MD
Consultant Pathologist