

Patient Name	Mrs. GEETA	Client Name	SRD Path Lab, Palwal	Specimen Received	23-Jun-2019
Age/Sex	35 Years/Female			Specimen Type	Tissue
Patient ID	011906230194			Collection Date	23-Jun-2019
Specimen ID	MOLQ/B-1186/19			Report Date	02-Jul-2019

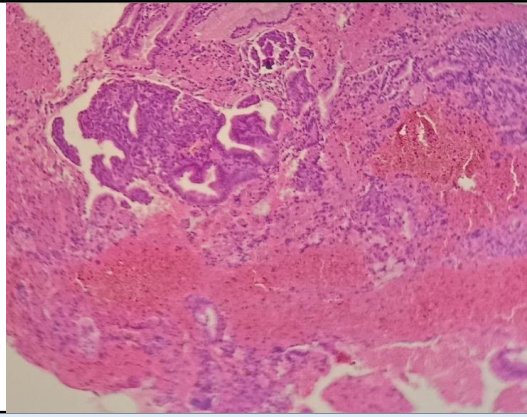
SURGICAL PATHOLOGY REPORT

Endometrial biopsy

DIAGNOSIS

IMPRESSION

ENDOCERVICAL POLYP WITH PROLIFERATIVE PHASE



SPECIMEN
Endometrial biopsy

GROSS
Received multiple grayish white tissue piece.


Microscopy

1. Section examined shows endocervical glands and mucosal lining epithelium having columnar cells with round to oval nucleus. Stroma shows mononuclear inflammatory cells. No granuloma and no malignant cells seen.

Note : All biopsy specimen will be stored for 15 (fifteen)days, block and slides for 5(five) years only from the time of receipt at the laboratory. No request ,for any of the above ,will be entertained after the due date.

Reference

- i) Rosai and Ackerman's Surgical Pathology.
- ii) Modern Surgical Pathology.



Gulshan Yadav, MD
Consultant Pathologist

Report generated at MolQ Laboratory, Gurgaon