

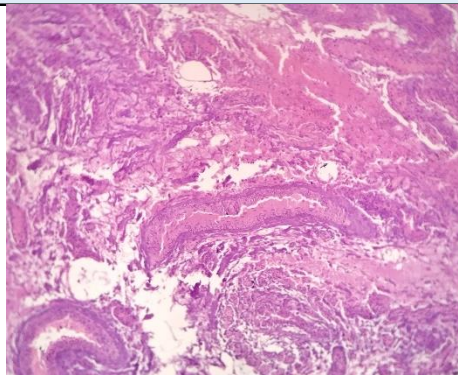
Patient Name TANGHCHACK	Mr. ABDUL GANI 596	Client Name Apollo Laboratories CC, Jammu & Kashmir	Specimen Received Specimen Type	21-Jun-2019 Tissue
Age/Sex	50 Years/Male		Collection Date	21-Jun-2019
Patient ID	011906210389		Report Date	02-Jul-2019
Specimen ID	MOLQ/B-1177-19			

SURGICAL PATHOLOGY REPORT

Neck cyst ?

DIAGNOSIS

Suggestive of cystic benign hyperkeratotic lesion.



SPECIMEN

Neck cyst ?

GROSS

Received two tissue piece 5x2,4x2cm with skin already cut open

Microscopy

1. Section examined shows Squamous lining epithelium with small round nucleus with hyperkeratosis and parakeratosis and keratin flakes. Deeper tissue shows glands, hairs, blood vessels, fibro collagenous tissue.
2. No granuloma and no malignant cells seen.

Note : All biopsy specimen will be stored for 15 (fifteen)days, block and slides for 5(five) years only from the time of receipt at the laboratory. No request ,for any of the above ,will be entertained after the due date.

Reference

- i) Rosai and Ackerman's Surgical Pathology.
- ii) Modern Surgical Pathology.

Gulshan Yadav, MD
Consultant Pathologist