

Patient Name TARATHPORA	Ms. FATIMA 552	Client Name Apollo Laboratories CC, Jammu & Kashmir	Specimen Received Specimen Type	18-Jun-2019 Tissue
Age/Sex	25 Years/Female		Collection Date	18-Jun-2019
Patient ID	011906180108		Report Date	02-Jul-2019
Specimen ID	MOLQ/B-1145-19			

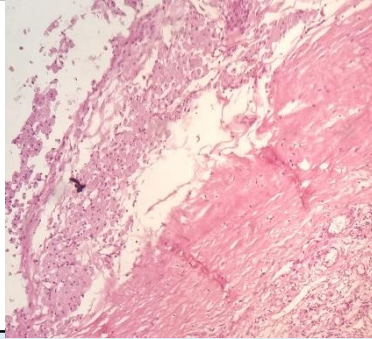
SURGICAL PATHOLOGY REPORT

Ovarian cyst mass

DIAGNOSIS

Simple ovarian cyst.

(Kindly co-relate clinically and radiologically)



SPECIMEN

Ovarian cyst mass

GROSS

Received multiple grayish white tissue piece, 3x2 cm in aggregate.

Microscopy

- Section examined shows ovarian tissue with luteal cyst with ? simple ovarian cyst lined by cuboidal lining epithelium.

Note : All biopsy specimen will be stored for 15 (fifteen)days, block and slides for 5(five) years only from the time of receipt at the laboratory. No request ,for any of the above ,will be entertained after the due date.

Reference

- Rosai and Ackerman's Surgical Pathology.
- Modern Surgical Pathology.

Gulshan Yadav, MD
Consultant Pathologist