

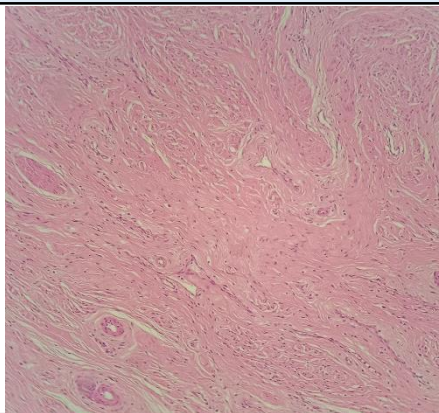
Patient Name	Mrs. ASTOONI	Client Name	MolQ Collection Centre CSK	Specimen Received	25-Jun-2019
Age/Sex	37 YRS/F	Hospital, Sohna		Specimen Type	Tissue
Patient ID	011906250316			Collection Date	25-Jun-2019
Specimen ID	MOLQ/B-1198/19			Report Date	29 June 2019

SURGICAL PATHOLOGY REPORT

Uterus with Cervix

DIAGNOSIS

CHRONIC CERVICITIS



SPECIMEN

Uterus with Cervix

GROSS

Received 8.2x6 cm uterus with cervix with bilateral adnexa. Ovary size 2x2 cm, 4x3 cm tube shows paratubal cyst.

Microscopy

Section examined shows

- 1) Endometrium with proliferative phase
- 2) Myometrium with superficial adenomyosis.
- 3) Cervix with mononuclear inflammatory cells
- 4) Ovary and tube unremarkable
- 5) Other with Hemorrhagic cyst and tube unremarkable

Note : All biopsy specimen will be stored for 15 (fifteen) days, block and slides for 5 (five) years only from the time of receipt at the laboratory. No request, for any of the above, will be entertained after the due date.

Reference

- i) Rosai and Ackerman's Surgical Pathology.
- ii) Modern Surgical Pathology.

Gulshan Yadav, MD
Consultant Pathologist