

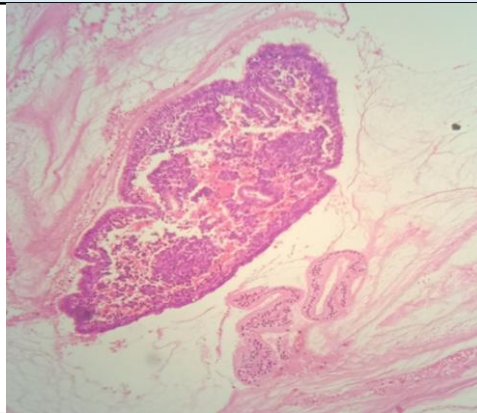
Patient Name	BISANI 33569	Client Name	Pushpanjali Hospital (Rewari)	Specimen Received	25-Jun-2019
Age/Sex	53 YRS/F	ReferBy	DR.RACHNA	Specimen Type	Tissue
Patient ID	011906250301			Collection Date	25-Jun-2019
Specimen ID	MOLQ/B-1196/19			Report Date	29 june 2019

SURGICAL PATHOLOGY REPORT

Endometrium

DIAGNOSIS

Endometrial polyp with early secretory phase



SPECIMEN

Endometrium

GROSS

Received multiple grayish white tissue piece.

Microscopy

Section examined shows small and broken endometrial glands with cuboidal lining epithelium. Stroma shows mononuclear inflammatory cells and fibrin.

Section also shows squamous metaplasia.

No granuloma and no malignant cells seen.

Note : All biopsy specimen will be stored for 15 (fifteen)days, block and slides for 5(five) years only from the time of receipt at the laboratory. No request ,for any of the above ,will be entertained after the due date.

Reference

- i) Rosai and Ackerman's Surgical Pathology.
- ii) Modern Surgical Pathology.

Gulshan Yadav, MD
Consultant Pathologist