

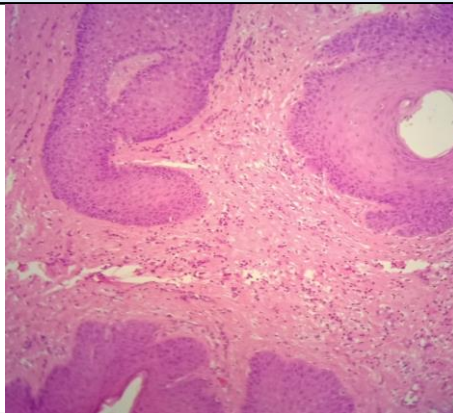
| | | | | | |
|---------------------|----------------|--------------------|-------------------------------|--------------------------|--------------|
| Patient Name | SUMITRA DEVI | Client Name | Pushpanjali Hospital (Rewari) | Specimen Received | 24-Jun-2019 |
| Age/Sex | 48 YRS/F | | | Specimen Type | Tissue |
| Patient ID | 011906240270 | | | Collection Date | 24-Jun-2019 |
| Specimen ID | MOLQ/B-1189/19 | | | Report Date | 29 june 2019 |

SURGICAL PATHOLOGY REPORT

Left breast papilloma

DIAGNOSIS

Papilloma



SPECIMEN

Left breast papilloma

GROSS

Received 0.5x0.5cm grayish white tissue piece.

Microscopy

Section examined shows Squamous lining epithelium with round to oval nucleus deeper tissue shows fibro collagenous tissue, blood vessels.Heavy inflammatory infiltrate(polymorphs ,lymphocytes , plasma cells).

Section also shows mild atypia in the lining epithelium with large nucleus.

Note : All biopsy specimen will be stored for 15 (fifteen)days, block and slides for 5(five) years only from the time of receipt at the laboratory. No request ,for any of the above ,will be entertained after the due date.

Reference

- i) Rosai and Ackerman's Surgical Pathology.
- ii) Modern Surgical Pathology.

Gulshan Yadav, MD
Consultant Pathologist