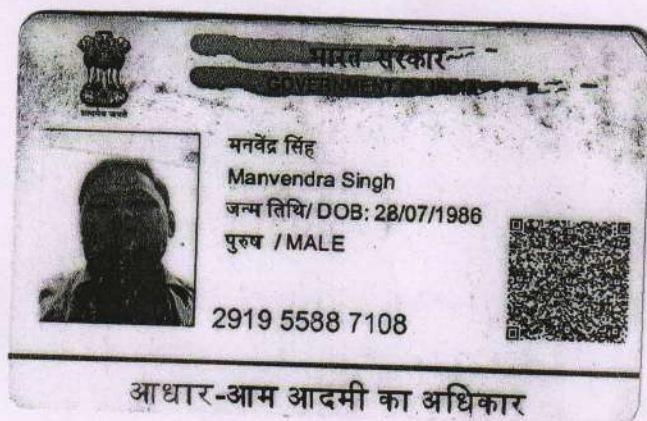

# CERTIFICATE OF MEDICAL FITNESS

This is to certify that I have conducted the clinical examination

of Manvendra Singh on \_\_\_\_\_

After reviewing the medical history and on clinical examination it has been found that he/she is

Tick	
<input type="checkbox"/>	• Medically Fit
<input type="checkbox"/>	• Fit with restrictions/recommendations
<p>Though following restrictions have been revealed, in my opinion, these are not impediments to the job.</p> <ol style="list-style-type: none"><li data-bbox="702 761 750 1512">1. <u>Mild dyslipidemia with Fatty Liver Gr. I-D</u></li><li data-bbox="758 761 805 1512">2. <u>Raised S. Bilirubin (Tud)</u></li><li data-bbox="813 761 861 1512">3. <u>Increased no. of Pus cells in urine</u></li></ol> <p>However the employee should follow the advice/medication that has been communicated to him/her.</p> <p>Review after <u>15d</u></p>	
<input type="checkbox"/>	• Currently Unfit. Review after _____ recommended
<input type="checkbox"/>	• Unfit

Dr. Arif  
Medical Officer  
The Apollo Clinic, ~~Hyderabad~~ **GUPTA**  
MBBS, MD  
Consulting Physician  
Regd. No. 7513 (HMC)

*This certificate is not meant for medico-legal purposes*



# विवेकानन्द आरोग्य केन्द्र

466 P, सेक्टर 12 A, नजदीक माधव भवन, गुरुग्राम  
(भारत विकास परिषद् महाराणा प्रताप न्यास, गुरुग्राम द्वारा संचालित)



## उपलब्ध ओ.पी.डी. सुविधाएँ

- हृदय रोग चिकित्सा (Cardiology)
- बाल एवं भ्रूण रोग चिकित्सा  
(Paediatrics & Fetal Medicine)
- बाल रोग चिकित्सा (Paediatrics)
- स्त्री रोग चिकित्सा (Gynaecology)
- हड्डियों रोग चिकित्सा (Orthopaedics)
- दन्त चिकित्सा (Dental Care)
- सामान्य चिकित्सा (General Physician)
- फिजियोथैरेपी (Physiotherapy)
- चर्म रोग चिकित्सा (Dermatology)
- मूत्र रोग चिकित्सा (Urology)
- गुदा रोग चिकित्सा (Nephrology)
- नाक, कान, गला रोग विशेषज्ञ (ENT)
- नेत्र रोग विशेषज्ञ (Ophthalmology)
- कैंसर रोग विशेषज्ञ (Oncology)
- IVF क्लिनिक

## डायलिसिस (Dialysis)

## उपलब्ध जाँच

- अल्ट्रासाउण्ड (Ultrasound)
- ईको (Echo)
- स्ट्रेस ईको (Stress Echo)
- टी.एम.टी. (T.M.T.)
- पी.एफ.टी. (Lung Function Test)
- ई.सी.जी. (E.C.G.)
- ई.ई.जी. (E.E.G.)
- एक्स-रे (X-Ray)
- मैमोग्राफी (Mammography)
- ओ.पी.जी. (Dental X-Ray)
- हॉल्टर टेस्ट (Holter Test)
- ऑडियॉमिट्री (Audiometry)

बच्चों एवं वयस्कों के टीकाकरण  
की सुविधा उपलब्ध है।

Name of patient: Mr. Manvendra Singh	Age: 33	M/F: M
Consultant:	Speciality: Package	
MR No : MR008720	Visit No: OP018378	Date: 22-06-2019

HT: 5'6"

WT: 83.5 kg

RA: 85 joint

PR: 120/80 mm Hg

Chest |  
CNS | ✓  
Abd | ✓

खून एवं मल-मूत्र की जाँच NABL द्वारा मान्यता प्राप्त MolQ लैब द्वारा की जाती है।

सम्पर्क सूत्र: 0124-2224102 / 103 / 104 | Mob.: 8683061905, 8683061906  
ओपीडी. पर्ती का शुल्क केवल तीन दिन के लिए मान्य रहेगा।

[www.vakhospital.com/in/co.in](http://www.vakhospital.com/in/co.in)



## Radiology Report

Name : Mr. Manvendra Singh  
Age/Gender : 33 Y/M  
Prescribed Doctor : Self

MR No : MR008720  
Visit ID : OP018378  
Report Date : 25-06-2019 11:12

## Ultrasound

### USG EXAMINATION : WHOLE ABDOMEN

Liver shows normal shape with **mild increase in size (15.6cm) with increased echogenicity, suggestive of fatty changes**. Intrahepatic biliary radicals are not dilated. No focal lesion is seen. **Portal Vein** shows normal calibre.

**Gall bladder** shows physiological distension and normal wall thickness. No calculus or mass is seen in the lumen.

**CBD** is normal in diameter. No calculus is seen

**Pancreas** is normal in size, shape and echo texture.

**Spleen** is normal in shape, size and echo texture.

**Right kidney** show normal shape & size. Cortico-medullary differentiation is maintained. Right kidney show no calculus or hydronephrosis.

**Left kidney** show normal shape & size. Cortico-medullary differentiation is maintained. Left kidney show no calculus or hydronephrosis.


No free fluid is seen in the intra-peritoneal cavity. No evidence of mesenteric lymphadenopathy is seen.

**Urinary bladder** is normal in shape, size and wall thickness. No mass or calculus is seen.

**Prostate** is normal in shape, size & echo texture.

**IMP : Borderline hepatomegaly with fatty liver grade I to II.**

PLEASE CORRELATE CLINICALLY.

  
Dr. Parvinder Loom  
MD ( Radio- diagnosis)



## Radiology Report

Name : Mr. Manvendra Singh  
Age/Gender : 33 Y/M  
Prescribed Doctor : Self

MR No : MR008720  
Visit ID : OP018378  
Report Date : 22-06-2019 17:14

## X-Ray

### X-RAY CHEST PA VIEW

Soft tissue and bony thoracic cage are normal.

Trachea is central.

Cardiac configuration is normal with normal cardio-thoracic ratio.

Pulmonary vasculature is within normal limits.

Both costo phrenic angles and domes of diaphragm are normal.

No pulmonary parenchymal lesion is seen.

PLEASE CORRELATE CLINICALLY.



DR.S.B. GANDHI  
MD (Radio-diagnosis)

# VIVEKANAND AROGYA KENDRA

**Patient Details**                      **Date:** 04-Jan-80                      **Time:** 1:38:36 AM  
**Name:** manvendra singh ID: MR008720  
**Age:** 33 y                      **Sex:** M                      **Height:** 56 ins                      **Weight:** 835 Kgs  
**Clinical History:** nothing significant

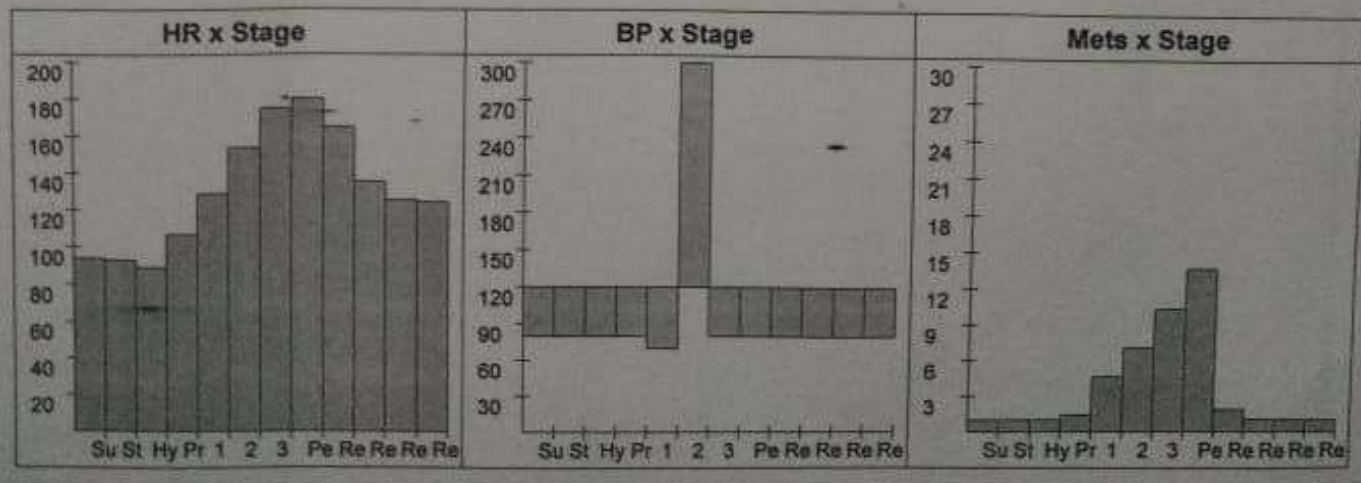
**Medications:** nil

## Test Details

**Protocol:** Bruce                      **Pr.MHR:** 187 bpm                      **THR:** 158 (85 % of Pr.MHR) bpm  
**Total Exec. Time:** 9 m 20 s                      **Max. HR:** 180 (96% of Pr.MHR) bpm                      **Max. Mets:** 13.50  
**Max. BP:** 120 / 80 mmHg                      **Max. BP x HR:** 21600 mmHg/min                      **Min. BP x HR:** 6230 mmHg/min  
**Test Termination Criteria:** THR achieved

## Protocol Details

Stage Name	Stage Time (min : sec)	Mets	Speed (mph)	Grade (%)	Heart Rate (bpm)	Max. BP (mm/Hg)	Max. ST Level (mm)	Max. ST Slope (mV/s)
Supine	0 : 19	1.0	0	0	94	120 / 80	-0.42 aVR	1.06 V2
Standing	0 : 18	1.0	0	0	93	120 / 80	-0.64 aVR	1.42 V2
Hyperventilation	0 : 18	1.0	0	0	89	120 / 80	-0.64 aVR	1.42 V2
1	3 : 0	4.6	1.7	10	129	120 / 70	-0.85 aVR	2.12 V3
2	3 : 0	7.0	2.5	12	154	120 / 800	-0.64 II	2.48 V3
3	3 : 0	10.2	3.4	14	175	120 / 80	-1.49 aVR	3.54 V3
Peak Ex	0 : 20	13.5	4.2	16	180	120 / 80	-1.27 aVR	3.54 V2
Recovery(1)	1 : 0	1.8	1	0	165	120 / 80	-1.49 aVR	5.66 V3
Recovery(2)	1 : 0	1.0	0	0	136	120 / 80	-1.49 aVR	5.66 V3
Recovery(3)	1 : 0	1.0	0	0	126	120 / 80	-0.85 aVR	4.60 V3
Recovery(4)	0 : 16	1.0	0	0	125	120 / 80	-0.64 aVR	2.48 V3



# VIVEKANAND AROGYA KENDRA

## Patient Details

Date: 04-Jan-80

Time: 1:38:36 AM

Name: manvendra singh ID: MR008720

Age: 33 y

Sex: M

Height: 56 ins

Weight: 835 Kgs

## Interpretation

No significant ST-T changes seen during TMT.  
TMT is negative for stress induced myocardial ischemia.  
Please correlate clinically.

Ref. Doctor: \_\_\_\_\_

( Summary Report edited by user )

**Dr. ARUN KUMAR GARG**  
MBBS, MDCC, FNIC, FICC  
Consultant, Cardiology  
Vivekanand Arogya Kendra  
Reg. No. HMC-8027