

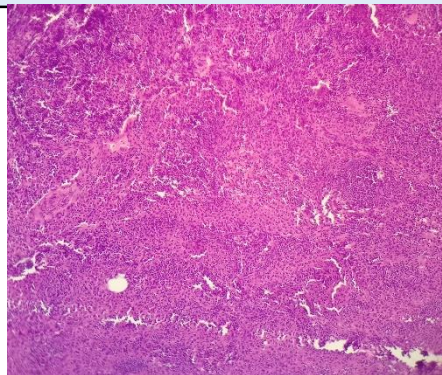
Patient Name	HIMANSHU	Client Name	Anupam Tomar Hospital	Specimen Received	18-Jun-2019
Age/Sex	11/Male			Specimen Type	Tissue
Patient ID	011906180429			Collection Date	18-Jun-2019
Specimen ID	MOLQ/B-1150-19			Report Date	28-Jun-2019

SURGICAL PATHOLOGY REPORT

Right Undescended Testes

DIAGNOSIS

ATROPHIC TESTES



SPECIMEN

Right Undescended Testes

GROSS

Received 1.0x1.5 cm greyish white tissue piece.

Microscopy

1. Section examined shows mononuclear immature spermatogenic cells surrounded by mononuclear inflammatory cells and fibrocollagenous tissue.
2. No granuloma seen. No malignant cells seen.

Note : All biopsy specimen will be stored for 15 (fifteen)days, block and slides for 5(five) years only from the time of receipt at the laboratory. No request ,for any of the above ,will be entertained after the due date.

Reference

- i) Rosai and Ackerman's Surgical Pathology.
- ii) Modern Surgical Pathology.

Gulshan Yadav, MD
Consultant Pathologist