

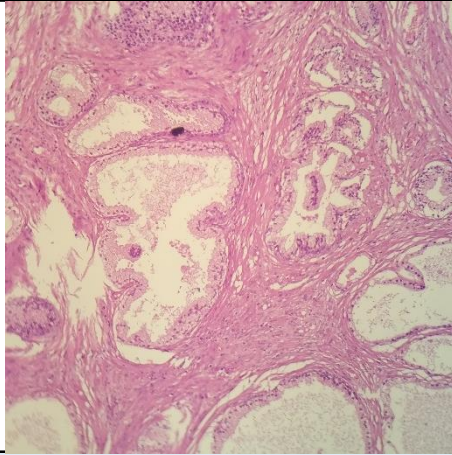
<b>Patient Name</b>	<b>Mr. POONAM CHAND</b>	<b>Client Name</b>	Pushpanjali Hospital	<b>Specimen Received</b>	22-Jun-2019
<b>Age/Sex</b>	71 Years/Male		(Rewari)	<b>Specimen Type</b>	Tissue
<b>Patient ID</b>	011906220228	<b>Client Code</b>	MolQ1789CM	<b>Collection Date</b>	22-Jun-2019
<b>Specimen ID</b>	MOLQ/B-1182/19	<b>Ref. Doc</b>	DR. S P Yadav	<b>Report Date</b>	27-Jun-2019

## SURGICAL PATHOLOGY REPORT

### TURP

#### DIAGNOSIS

#### **BENIGN PROSTATIC HYPERPLASIA WITH PROSTATITIS**



#### **SPECIMEN**

TURP

#### **GROSS**

Received multiple grayish white tissue piece, 3x3 cm in aggregate weight 10 grams.

#### **Microscopy**

1. Section examined shows bilayered prostatic glands with columnar lining epithelium and with small round to oval nucleus surrounded by large number of fibrocollagenous tissue and mononuclear inflammatory cell.
2. No granuloma seen. No malignant cells seen.

**Note :** All biopsy specimen will be stored for 15 (fifteen)days, block and slides for 5(five) years only from the time of receipt at the laboratory. No request ,for any of the above ,will be entertained after the due date.

#### **Reference**

- i) Rosai and Ackerman's Surgical Pathology.
- ii) Modern Surgical Pathology.

**Gulshan Yadav, MD  
Consultant Pathologist**