

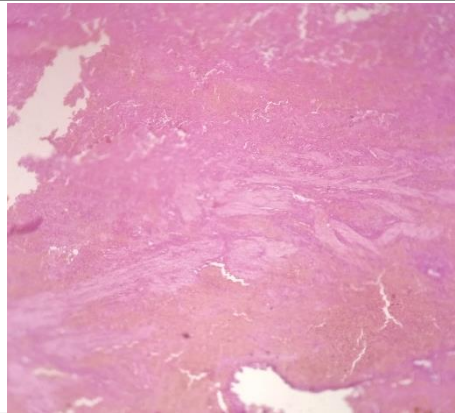
Patient Name	Mrs. SUMA Haidar	Client Name	Chetanya Hospital, Gurgaon	Specimen Received	21-Jun-2019
Age/Sex	37 Years/Female			Specimen Type	Tissue
Patient ID	011906210066			Collection Date	21-Jun-2019
Specimen ID	MOLQ/B-1179/19			Report Date	27-Jun-2019

SURGICAL PATHOLOGY REPORT

GALL BLADDER.

DIAGNOSIS

CHOLECYSTITIS AND CHOLELITHIASIS.



SPECIMEN

Gall Bladder.

GROSS

Received 6x2.3cm long gall bladder. Cut section shows stones with mucoid material.

Microscopy

- Section examined shows ulcerative mucosa and Rokitansky-Aschoff sinuses (irregularly shaped tubular structures lined by cuboidal lining epithelium with round to oval nucleus) with fibro collagenous tissue and inflammatory cells (lymphocytes).

Note : All biopsy specimen will be stored for 15 (fifteen) days, block and slides for 5 (five) years only from the time of receipt at the laboratory. No request ,for any of the above will be entertained after the due date.

Reference

- Rosai and Ackerman's Surgical Pathology.
- Modern Surgical Pathology.

Gulshan Yadav, MD
Consultant Pathologist