

Patient Name Ms. TALIMA
Age/Sex 15 Years/Female
Patient ID 011906190362
Specimen ID MOLQ/B-1161-19

Client Name Vedic Hospital,
Gurgaon

Specimen Received 19-Jun-2019
Specimen Type Tissue
Collection Date 19-Jun-2019
Report Date 27-Jun-2019

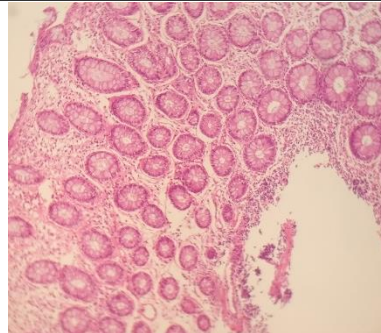
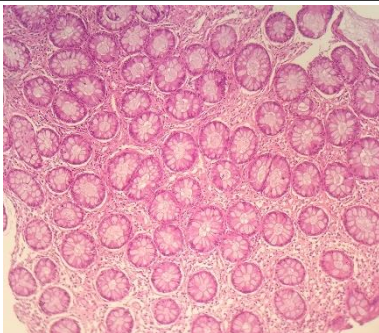
SURGICAL PATHOLOGY REPORT

Abdominal Koch's

DIAGNOSIS

Non specific inflammation.

Advised: Clinical co-relation



SPECIMEN

Abdominal Koch's

GROSS

(Container 1)Received multiple greyish white tissue piece,
(Container 2)Received multiple greyish white tissue piece.


Microscopy

1. Section examined shows mucosal with submucosal glands, columnar lining epithelium with small round to oval nucleus with occasional histiocytes.
2. No granuloma and no malignant cells seen.

Note : All biopsy specimen will be stored for 15 (fifteen)days, block and slides for 5(five) years only from the time of receipt at the laboratory. No request ,for any of the above ,will be entertained after the due date.

Reference

- i) Rosai and Ackerman's Surgical Pathology.
- ii) Modern Surgical Pathology.



Gulshan Yadav, MD
Consultant Pathologist