

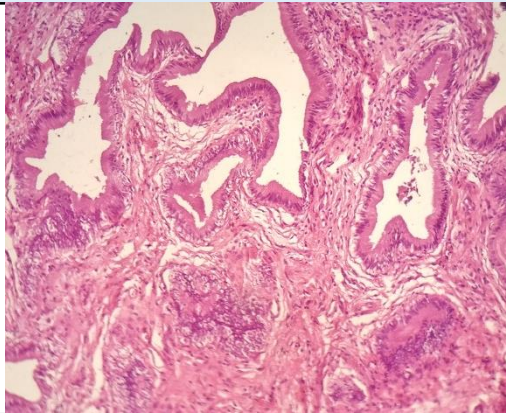
<b>Patient Name</b>	SHAKEELA KUNAN	<b>Client Name</b>	Bandipora Collection Centre,	<b>Specimen Received</b>	14/06/2019
<b>Age/Sex</b>	36 Years/Female		Jammu & Kashmir	<b>Specimen Type</b>	Tissue
<b>Patient ID</b>	011906140267			<b>Collection Date</b>	14/06/2019
<b>Specimen ID</b>	MOLQ/B-1121/19			<b>Report Date</b>	24/06/2019

## SURGICAL PATHOLOGY REPORT

### GALL BLADDER.

#### DIAGNOSIS

**CHOLECYSTITIS WITH CHOLELITHIASIS**



#### SPECIMEN

Gall Bladder.

#### GROSS

Received 3x2.1cm long greyish white tissue piece.  
Cut section shows no stones.

#### Microscopy

- Section examined shows ulcerative mucosa and Rokitansky-Aschoff sinuses (irregularly shaped tubular structures lined by cuboidal lining epithelium with round to oval nucleus) with fibro collagenous tissue and inflammatory cells (lymphocytes).

**Note :** All biopsy specimen will be stored for 15 (fifteen) days, block and slides for 5 (five) years only from the time of receipt at the laboratory. No request, for any of the above, will be entertained after the due date.

#### Reference

- Rosai and Ackerman's Surgical Pathology.
- Modern Surgical Pathology.

**Gulshan Yadav, MD**  
Consultant Pathologist