

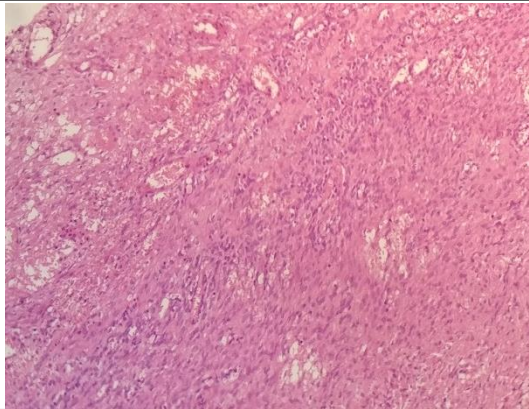
<b>Patient Name</b>	<b>Ms. MUNNI DEVI 32978</b>	<b>Client Name</b>	Pushpanjali Hospital	<b>Specimen Received</b>	14/06/2019
<b>Age/Sex</b>	45 Years/Female		(Rewari)	<b>Specimen Type</b>	Tissue
<b>Patient ID</b>	011906140251	<b>Client Code</b>	MolQ1789CM	<b>Collection Date</b>	14/06/2019
<b>Specimen ID</b>	MOLQ/B-1117/19	<b>Ordering Physician</b>	DR.RACHNA	<b>Report Date</b>	24/06/2019

**SURGICAL PATHOLOGY REPORT**

Walved biopsy ?

**DIAGNOSIS**

**Benign cystic lesion with inflammation.**



**SPECIMEN**

Walved biopsy ?

**GROSS**

Received very tiny tissue piece.

**Microscopy**

Section examined shows squamous lining epithelium with round nucleus mild hyperkeratosis and Parakeratosis. Deeper tissue shows fibro collagenous with inflammatory cells and RBCs. No granuloma and no malignant cells seen.

**Note :** All biopsy specimen will be stored for 15 (fifteen)days, block and slides for 5(five) years only from the time of receipt at the laboratory. No request ,for any of the above ,will be entertained after the due date.

**Reference**

- i) Rosai and Ackerman's Surgical Pathology.
- ii) Modern Surgical Pathology.

**Gulshan Yadav, MD  
Consultant Pathologist**