

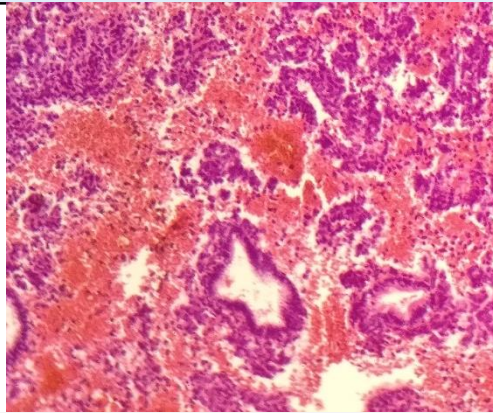
<b>Patient Name</b>	<b>Ms. SUNITA 32968</b>	<b>Client Name</b>	Pushpanjali Hospital,	<b>Specimen Received</b>	14/06/2019
<b>Age/Sex</b>	40 Years/Female		(Rewari)	<b>Specimen Type</b>	Tissue
<b>Patient ID</b>	011906140245	<b>Client Code</b>	MolQ1789CM	<b>Collection Date</b>	14/06/2019
<b>Specimen ID</b>	MOLQ/B-1116/19	<b>Ordering Physician</b>	DR.RACHNA	<b>Report Date</b>	24/06/2019

**SURGICAL PATHOLOGY REPORT**

**Endometrial biopsy**

**DIAGNOSIS**

**Kindly co-relate Clinically.**



**SPECIMEN**

Endometrial biopsy

**GROSS**

Received multiple greyish white tissue piece.

**Microscopy**

Section examined shows autolyzed tissue with few broken endometrial glands with round nucleus and fibrin. Stroma shows mononuclear inflammatory cells with RBCs. No granuloma and no malignant cells.

**Note :** All biopsy specimen will be stored for 15 (fifteen)days, block and slides for 5(five) years only from the time of receipt at the laboratory. No request ,for any of the above ,will be entertained after the due date.

**Reference**

- i) Rosai and Ackerman's Surgical Pathology.
- ii) Modern Surgical Pathology.

**Gulshan Yadav, MD  
Consultant Pathologist**