

Patient Name	Mr. ALAM	Client Name	Sushyam Family Clinic	Specimen Received	16-Jun-2019
Age/Sex	40 Years/Male			Specimen Type	Tissue
Patient ID	011906160095	Client Code		Collection Date	16-Jun-2019
Specimen ID	MOLQ/B-1134-19	Ref. Doctor		Report Date	24-Jun-2019

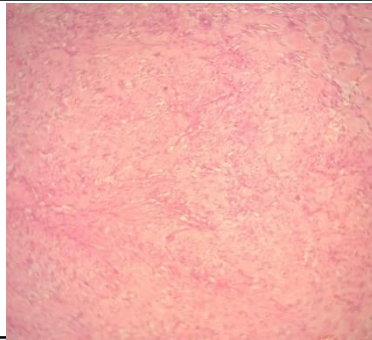
SURGICAL PATHOLOGY REPORT

Soft Tissue Tumor (Scapular Region).

DIAGNOSIS

SUGGESTIVE OF **BENIGN MESENCHYMAL LESION.**

Advised: Immunohistochemistry for confirmation. (a-SMA, Vimentin, Desmin and S-100)



SPECIMEN

Soft Tissue Tumor (Scapular Region).

GROSS

Received 5.4x4.6 cm greyish white tissue piece.

Microscopy

1. Section examined shows fibrocollagenous tissue arranged in bundles and in fascicles. Cells shows oval plump nucleus.
2. Section also shows blood vessels in between.

Note : All biopsy specimen will be stored for 15 (fifteen)days, block and slides for 5(five) years only from the time of receipt at the laboratory. No request ,for any of the above ,will be entertained after the due date.

Reference

- i) Rosai and Ackerman's Surgical Pathology.
- ii) Modern Surgical Pathology.

Gulshan Yadav, MD
Consultant Pathologist