

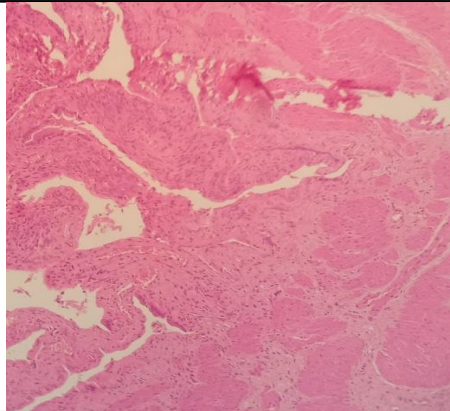
<b>Patient Name</b>	<b>Mr. AARIF 9275</b>	<b>Client Name</b>	Patients Care Clinical	<b>Specimen Received</b>	01-Jun-2019
<b>Age/Sex</b>	18 Years/Male		Laboratory, Jammu & Kashmir	<b>Specimen Type</b>	Tissue
<b>Patient ID</b>	011905300280			<b>Collection</b>	01-Jun-2019
<b>Specimen ID</b>	MOLQ/B-1030/19			<b>Report Date</b>	20/06/19

## SURGICAL PATHOLOGY REPORT

### Supraclavicular area

#### DIAGNOSIS

**Dermoid cyst**



#### SPECIMEN

Supraclavicular area

#### GROSS

Received 1x2cm greyish white tissue piece.

#### Microscopy

Section examined shows squamous lining epithelium with fibro collagenous tissue and hairs, sebaceous glands with keratin flakes and inflammatory cells, lymphocytes and macrophages.

**Note :** All biopsy specimen will be stored for 15 (fifteen)days, block and slides for 5(five) years only from the time of receipt at the laboratory. No request ,for any of the above ,will be entertained after the due date.

#### Reference

- i) Rosai and Ackerman's Surgical Pathology.
- ii) Modern Surgical Pathology.

**Gulshan Yadav, MD**  
Consultant Pathologist