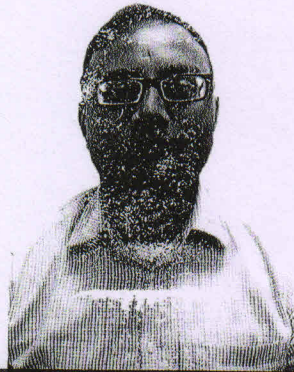

Padam
Gupta



BA Continuum India Pvt. Ltd.

A nonbank subsidiary of Bank of America Corporation

भारत निर्वाचन आयोग
पहचान पत्र
ELECTION COMMISSION OF INDIA
IDENTITY CARD

SEL0942326



निर्वाचक का नाम :
पदम गुप्ता
Elector's Name :
PADAM GUPTA
पिता का नाम : महेश शंकर गुप्ता
Father's Name : MAHESH SHANKAR GUPTA
लिंग / Sex : पुरुष / Male
जन्मतिथि DOB : XX/XX/1985

CERTIFICATE OF MEDICAL FITNESS

This is to certify that I have conducted the clinical examination

of Padam Supte on _____

After reviewing the medical history and on clinical examination it has been found that he/she is

	Tick
<ul style="list-style-type: none"> • Medically Fit 	<input type="checkbox"/>
<ul style="list-style-type: none"> • Fit with restrictions/recommendations <p>Though following restrictions have been revealed, in my opinion, these are not impediments to the job.</p> <p>1. <u>Mild Dyslipidemia</u></p> <p>2. <u>Fatty Liver Gr I</u></p> <p>3. <u>Mild Anaemic</u></p> <p>However the employee should follow the advice/medication that has been communicated to him/her.</p> <p>Review after <u>6m</u></p>	<input type="checkbox"/>
<ul style="list-style-type: none"> • Currently Unfit. <p>Review after _____ recommended</p>	<input type="checkbox"/>
<ul style="list-style-type: none"> • Unfit 	<input type="checkbox"/>

Dr. A.K.S
Medical Officer
The Apollo Clinic, (Location)

DR. ASHOK K. GUPTA
MBBS, MD
Consulting Physician
Regd. No. 7513 (HMC)

This certificate is not meant for medico-legal purposes

उपलब्ध ओ.पी.डी. सुविधाएँ

- हृदय रोग चिकित्सा
(Cardiology)
- बाल एवं भ्रूण रोग चिकित्सा
(Paediatrics & Fetal Medicine)
- बाल रोग चिकित्सा
(Paediatrics)
- स्त्री रोग चिकित्सा
(Gynaecology)
- हड्डी रोग चिकित्सा
(Orthopaedics)
- दन्त चिकित्सा
(Dental Care)
- सामान्य चिकित्सा
(General Physician)
- फिजियोथैरेपी
(Physiotherapy)
- चर्म रोग चिकित्सा
(Dermatology)
- मूत्र रोग चिकित्सा
(Urology)
- गुर्दा रोग चिकित्सा
(Nephrology)

उपलब्ध जाँच

- डायलिसिस (Dialysis)
- अल्ट्रासाउण्ड (Ultrasound)
- ईको (Echo)
- स्ट्रेस ईको (Stress Echo)
- टी.एम.टी. (T.M.T.)
- पी.एफ.टी. (Lung Function Test)
- ई.सी.जी. (E.C.G.)
- ई.ई.जी. (E.E.G.)
- एक्स-रे (X-Ray)
- मैमोग्राफी (Mammography)
- ओ.पी.जी. (Dental X-Ray)
- हॉल्टर टेस्ट (Holter Test)

Ref. No.:.....

Date:.....

Name of patient: Mr. Padam Gupta	Age: 33	M/F: M
Consultant:	Speciality: Package	
MR No : MR008289	Visit No: OP017404	Date: 12-06-2019

5'6"
Wt. 78 kg
RR = 84 /min
Bp = 120/70 mmHg

Not for Medico Legal Purpose

रून एवं मल-मूत्र की जाँच NABL द्वारा मान्यता प्राप्त MoIQ लैब द्वारा की जाती है।

सम्पर्क सूत्र: 0124-2224102 / 103 / 104 | Mob.: 8683061905, 8683061906

ओ.पी.डी. पर्ची का शुल्क केवल तीन दिन के लिए मान्य रहेगा।

Radiology Report

Name : Mr. Padam Gupta
Age/Gender : 33 Y/M
Prescribed Doctor : Self

MR No : MR008289
Visit ID : OP017404
Report Date : 12-06-2019 09:53

Ultrasound

USG EXAMINATION : WHOLE ABDOMEN

Liver shows normal shape and size **with mildly increased echogenicity, suggestive of fatty change.** Intrahepatic biliary radicals are not dilated. No focal lesion is seen. **Portal Vein** shows normal calibre. **Gall bladder** shows physiological distension and normal wall thickness. No calculus or mass is seen in the lumen.

CBD is normal in diameter. No calculus is seen

Pancreas is normal in size, shape and echo texture.

Spleen is normal in shape, size and echo texture.

Right kidney show normal shape & size. Cortico-medullary differentiation is maintained. Right kidney show no calculus or hydronephrosis.

Left kidney show normal shape & size. Cortico-medullary differentiation is maintained. Left kidney show no calculus or hydronephrosis.


No free fluid is seen in the intra-peritoneal cavity. No evidence of mesenteric lymphadenopathy is seen.

Urinary bladder is normal in shape, size and wall thickness. No mass or calculus is seen.

Prostate is normal in shape, size & echo texture.

Imp:- Fatty liver grade-I.

PLEASE CORRELATE CLINICALLY.


Dr. Pawan Joon
MD (Radio- diagnosis)

Radiology Report

Name : Mr. Padam Gupta
Age/Gender : 33 Y/M
Prescribed Doctor : Self

MR No : MR008289
Visit ID : OP017404
Report Date : 12-06-2019 15:02

X-Ray

X-RAY CHEST PA VIEW

Bilateral lung fields appears to be clear. No obvious pulmonary parenchymal lesion is seen.


Trachea is central.

Cardiac configuration appears to be normal with normal cardio-thoracic ratio.

Both costo phrenic angles and domes of diaphragm are normal.

Visualized soft tissue and bony thoracic cage appears to be normal.

PLEASE CORRELATE CLINICALLY.



DR. PAWAN JOON
MD (Radio-diagnosis)

VIVEKANAND AROGYA KENDRA

Patient Details Date: 04-Jan-80 Time: 12:21:20 PM
Name: PADAM GUPTA ID: MR8289
Age: 33 y **Sex:** M **Height:** 66 cms **Weight:** 78 Kgs
Clinical History: NOTHING SIGNIFICANT

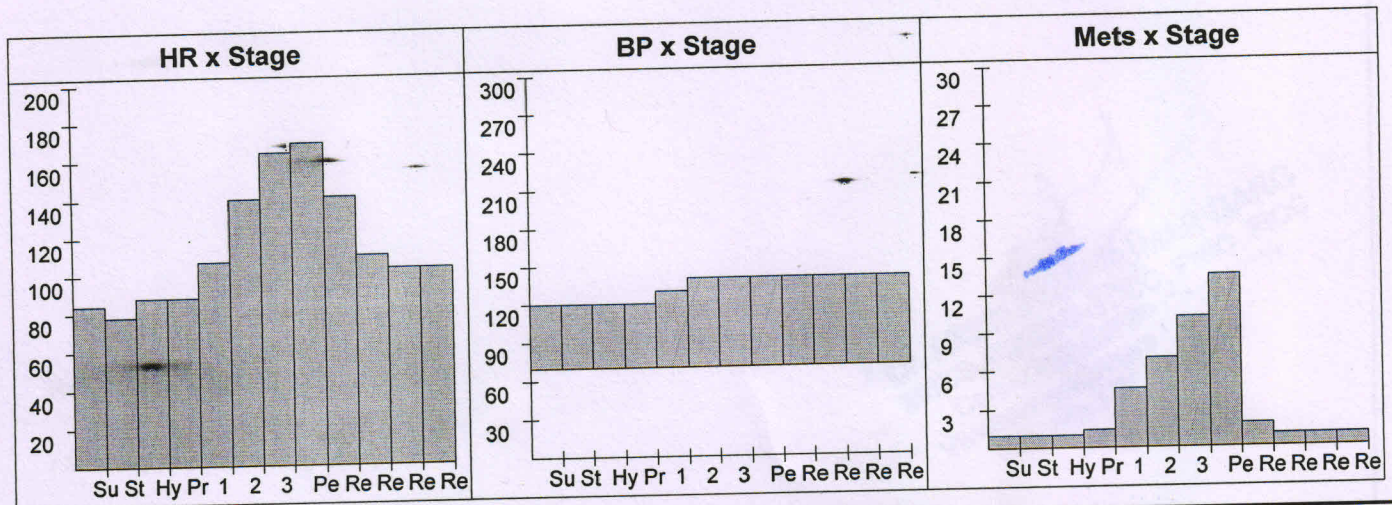
Medications: NIL

Test Details

Protocol: Bruce **Pr.MHR:** 187 bpm **THR:** 168 (90 % of Pr.MHR) bpm
Total Exec. Time: 9 m 22 s **Max. HR:** 169 (90% of Pr.MHR) bpm **Max. Mets:** 13.50
Max. BP: 140 / 70 mmHg **Max. BP x HR:** 23660 mmHg/min **Min. BP x HR:** 5460 mmHg/min
Test Termination Criteria: THR achieved

Protocol Details

Stage Name	Stage Time (min : sec)	Mets	Speed (mph)	Grade (%)	Heart Rate (bpm)	Max. BP (mm/Hg)	Max. ST Level (mm)	Max. ST Slope (mV/s)
Supine	0 : 33	1.0	0	0	84	120 / 70	-1.70 aVR	2.48 V2
Standing	0 : 16	1.0	0	0	78	120 / 70	-1.70 aVR	2.83 V2
Hyperventilation	0 : 29	1.0	0	0	88	120 / 70	-1.70 aVR	2.48 V2
1	3 : 0	4.6	1.7	10	107	130 / 70	-1.91 aVR	3.18 V3
2	3 : 0	7.0	2.5	12	140	140 / 70	-4.67 aVR	5.66 I
3	3 : 0	10.2	3.4	14	164	140 / 70	-2.76 II	3.18 V3
Peak Ex	0 : 22	13.5	4.2	16	169	140 / 70	-2.55 III	3.18 V3
Recovery(1)	1 : 0	1.8	1	0	141	140 / 70	-3.82 II	4.60 V3
Recovery(2)	1 : 0	1.0	0	0	110	140 / 70	-1.49 aVR	5.31 V3
Recovery(3)	1 : 0	1.0	0	0	103	140 / 70	-1.49 aVR	4.25 V3
Recovery(4)	0 : 26	1.0	0	0	103	140 / 70	-1.06 aVR	2.83 V3



VIVEKANAND AROGYA KENDRA

Patient Details

Date: 04-Jan-80

Time: 12:21:20 PM

Name: PADAM GUPTA ID: MR8289

Age: 33 y

Sex: M

Height: 66 cms


Weight: 78 Kgs

Interpretation

No significant ST-T changes seen during stress testing.
TMT is negative for stress induced myocardial ischemia seen.
Please correlate clinically.

Ref. Doctor: -----

(Summary Report edited by user)


Dr. ARUN KUMAR GARG
MBBS, MD, DNB, FIC, FNIC, FICC
Consultant Cardiologist
Vivekanand Arogya Kendra
Reg. No. 4111